

Immunohistochemical Distributuon of COX-1, COX-2, and TGFβ-1 in the Duodenum of Rats Treated with Capsaicin

Buket BAKIR¹  Sevda ELİŞ YILDIZ² Ebru KARADAĞ SARI³
Hasan ASKER³ Mümtaz NAZLI⁴

¹ Department of Histology - Embryology, Faculty of Veterinary Medicine, Namik Kemal University, TR-59000 Tekirdag - TURKEY

² School of Health Sciences, Kafkas University, TR-36040 Kars - TURKEY

³ Department of Histology - Embryology, Faculty of Veterinary Medicine, Kafkas University, TR-36040 Kars - TURKEY

⁴ Department of Histology - Embryology, Faculty of Medicine, Mugla Sıtkı Kocman University, TR-48000 Mugla - TURKEY

Article Code: KVFD-2015-14559 Received: 25.10.2015 Accepted: 04.03.2016 Published Online: 04.03.2016

Abstract

The purpose of this study was to investigate the effects of capsaicin on the duodenal distribution of cyclooxygenase-1 (COX-1), cyclooxygenase-2 (COX-2) and Transforming growth factor β-1 (TGFβ-1) in rats. Rats were divided into two groups (n =10 in each group). Experimental group treated with capsaicin (1 mg/kg, subcutaneously) was injected in 10% ethanol, 1% Tween and 80% distilled water everyday for a period of one week and in not injected control group. Localisations of COX-1, COX-2 and TGFβ-1 were observed in villus and crypt epithelial cells, and smooth muscle cells. In conclusion, in this study, capsaicin administration was found to increase the release of COX-1 and COX-2, and TGFβ-1.

Keywords: Capsaicin, Cyclooxygenase, Duodenum, Transforming growth factor β-1

Capsaicin Uygulanan Sıçanların Duodenumda COX-1, COX-2 ve TGFβ-1'in İmmünohistokimyasal Dağılımı

Özet

Bu çalışmada capsaicin uygulanan ratların duodenum dokusunda siklooksijenaz-1 (COX-1), siklooksijenaz-2 (COX-2) ve transforme edici büyüme faktörü β-1 (TGFβ-1)'in dağılımını araştırmak amaçlandı. Ratlar iki gruba ayrıldı (her grupta n=10). Capsaicin uygulanan deneme grubuna (1 mg/kg, subkutan yolla) %10 ethanol, %1 tween, %80 distile su karışımı bir haftalık periyot boyunca hergün enjekte edildi. COX-1, COX-2 ve TGFβ-1'in dağılımı villus ve kript epitel hücreleri ve düz kas hücrelerinde tespit edildi. Sonuçta, bu çalışmada capsaicin uygulamasının COX-1 ve COX-2 ve TGFβ-1 salınımını arttırdığı tespit edildi.

Anahtar sözcükler: Capsaicin, Siklooksijenaz, Duodenum, Transforme edici büyüme faktörü β-1

INTRODUCTION

Capsaicin is an active component of chili peppers, which are plants belonging to the genus *Capsicum annuum* [1,2]. In alternative medicine, it is used for relieving pains such as neuropathic pains, arthritis, pains after chemotherapy [3]. And it has analgesic effect [4,5]. It is also noted that it has effect on growth and development by increasing the release of growth factors [2,6-8].

It has been known for years that non-steroidal anti-inflammatory drugs (NSAIDs) such as aspirin, ibuprofen, and acetaminophen, provide relief from fever, pains, and

inflammation through their actions on cyclooxygenase (COX) enzymes [9]. COX is the enzyme that catalyzes the first two steps in the biosynthesis of the prostaglandins from the substrate arachidonic acid [10].

Two COX isozymes, COX-1 and COX-2, have been identified. Although both enzymes have similar functions, their temporal and spatial expression patterns are very different. COX-1 is constitutively expressed in many tissues, including the gastrointestinal mucosa [11]. In contrast, COX-2, is normally undetectable in most tissues; however, increased expression of COX-2 express inflammatory conditions of the gastrointestinal tract (e.g., inflammatory bowel



İletişim (Correspondence)



+90 282 2504715



buhal@hotmail.com

disease) [12]. This simple distinction, implying that COX-1 is constitutive and COX-2 inducible in nature, has been questioned on the basis of evidence about the constitutive expression of COX-2 in normal tissues, such as brain, kidney and blood vessel [13].

Transforming growth factor- β (TGF- β) is a growth factor which release from almost every tissue in mammals [14]. It consist of three members (TGF- β_1 , TGF- β_2 ve TGF- β_3) [15]. This family regulate numerous biological activities, including cell proliferation, differentiation, adhesion, and apoptosis, extracellular matrix (ECM) production, and early embryo development and immunity [16]. It was demonstrated that TGF- β localised in villus and crypt epithelial cells in small intesine [17,18].

With this study, it was aimed to investigate the effects of capsaicin, which was found to benefits such as have analgesic [3] and growth promoting [6,9], on the secretion of COX-1 that is protective for physiological functions of duodenal tissues [20], COX-2 that is suppressor in pathological situations [21] and TGF- β_1 that acts as regulatory as well as serving growth and development functions [16].

MATERIAL and METHODS

Animals and Experimental Design

Tissue samples were collected in compliance with an approved Kafkas University Institutional Animal Care and Use Committee Protocol (KAU-HADYEK/2014-033).

Twenty 50 days old male Spraque Dawley rats were randomly divided into two groups as; experimental (n=10) and control (n=10). Rats were housed in a continuously ventilated room at a mean temperature of $22\pm 2^\circ\text{C}$ with a lighting period of 12 h dark and 12 light. Animals were fed standard rodent chow (Bayramoğlu, Erzurum, Turkey) and water ad libitum. The amount of capsaicin used in our study was based on studies conducted by Moran et al. [22] and Tütüncü [23]. For the rats in experimental group, 1 mg/kg of capsaicin (cat no. M 2028, Sigma - Aldrich, Germany) was dissolved in 10% ethanol and mixed with 1% Tween (cat no. M 8170772100, Merck, USA) and 80% distilled water. Capsaicin solution was freshly prepared according to daily body weights of the rats and injected subcutaneously with an insulin injector at the same time every day for a week. For the rats in control group had no application.

After one week, all rats were sacrificed by cervical dislocation method under diethylether anaesthesia and duodenum samples were taken.

Immunohistochemical Procedure

For immunohistochemistry, the sections were incubated in 3% H_2O_2 for 10 min to inhibit endogenous peroxidase activity after undergoing deparaffinization and rehydration. Maximum heat was applied in a microwave for 10 min

in citrate buffer solution to reveal antigens, after being washed with PBS (Phosphate Buffer Saline). Sections were then incubated with primary antibodies anti-COX-1 (5F6/F4, ab695, abcam), anti-COX-2 (M-19, sc-1747, Santa Cruz) diluted to 1 : 200 in PBS at room temperature for one hour and polyclonal goat anti-TGF β -1 (sc-90, SantaCruz, USA) diluted 1 : 100 in PBS. Only PBS was dripped on the tissues of the negative control group. Streptavidin - biotin peroxidase technique was used after primary antibody incubation. Streptavidin - HRP (Horse Radish Peroxidase) (Invitrogen Histostain plus Broad Spectrum (AEC) Ref. 85.9943) was dripped on the sections, and then incubated at room temperature for 15 min. 3,3'-Diaminobenzidine tetrahydrochloride (0.5 mg/mL; Dako Corp.) was used as chromogen followed by hematoxylin counterstaining. Sections were mounted with immunoMount and examined by light microscope (Olympus BX51, Shinjuku, Tokyo Japan). Scoring was conducted using a semi-quantitative method [6] on an area of the sections, based on criteria of the percentage of stained cells and the degree of staining. The degree of staining was evaluated as follows; no reaction (-), slight (+), moderate (++) and intensive (+++).

RESULTS

It was observed normal histological structure in two groups.

COX-1 Immunoreactivity in Duodenum

While intensive cytoplasmic reaction was observed in villus epithelial cells and in crypt epithelial cells of experimental group, slight cytoplasmic reaction was observed in villus epithelial cells and in crypt epithelial cells of control group. No reaction was observed in goblet cells of all group. Intensive cytoplasmic reaction was present in smooth muscle cells of experimental group and slight cytoplasmic reaction was present in smooth muscle cells of control group (Fig. 1, Table 1).

COX-2 Immunoreactivity in Duodenum

Moderate cytoplasmic reaction was observed in villus epithelial cells and in crypt epithelial cells of experimental group. Slight cytoplasmic reaction was present in villus epithelial cells and in crypt epithelial cells of control group. No reaction was determined in goblet cells of all groups and intensive reaction was remerkable in connective tissue

Table 1. Comparison of COX-1 immunoreactivity's degree among groups

Tablo 1. Gruplar arasında COX-1 immünoreaktivitesinin karşılaştırılması

Duodenum (COX - 1)	Experimental Group	Control Group
Villus epithelial cells	+++	+
Cyript epithelial cells	+++	+
Goblet cells	-	-
Smooth muscle cells	+++	+

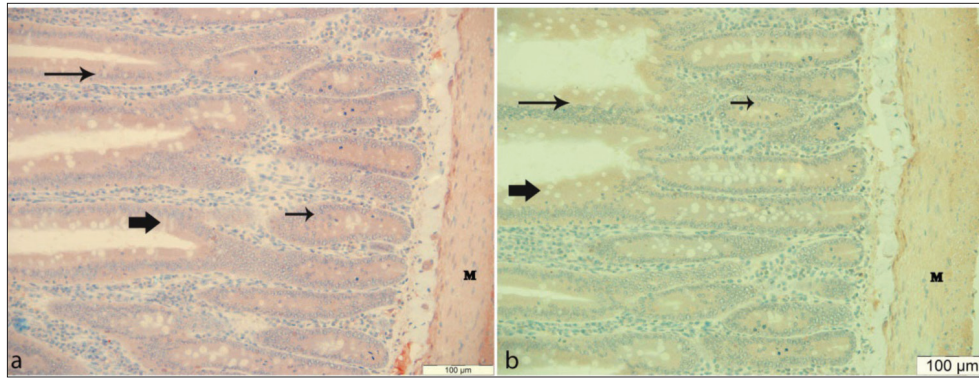


Fig 1. COX-1 immunoreactivity in rat duodenum. **a:** Experimental group, **b:** control group, Villus epithelial cell (long arrow), goblet cell (thick arrows), crypt epithelial cell (short arrow), smooth muscle cell (M). Immunohistochemistry, Bar: 100 µm

Şekil 1. Rat duodenumunda COX-1 immünoreaktivitesi. **a:** Deney grubu, **b:** kontrol grubu, Villus epitel hücreleri (uzun ok), goblet hücresi (kalın ok), kript epitel hücresi (kısa ok), düz kas hücresi (M). İmmünohistokimya, Bar: 100 µm

Table 2. Comparison of COX-2 immunoreactivity's degree among groups

Tablo 2. Gruplar arasında COX-2 immünoreaktivitesinin karşılaştırılması

Duodenum (COX-2)	Experimental Group	Control Group
Villus epithelial cells	++	+
Crypt epithelial cells	++	+
Goblet cells	-	-
Connective tissue cell	+++	++
Smooth muscle cells	++	+

Table 3. Comparison of TGFβ-1 immunoreactivity's degree among groups

Tablo 3. Gruplar arasında TGFβ-1 immünoreaktivitesinin karşılaştırılması

Duodenum (TGFβ - 1)	Experimental Group	Control Group
Villus epithelial cells	+++	+
Crypt epithelial cells	+++	+
Goblet cells	-	-
Smooth muscle cells	++	+

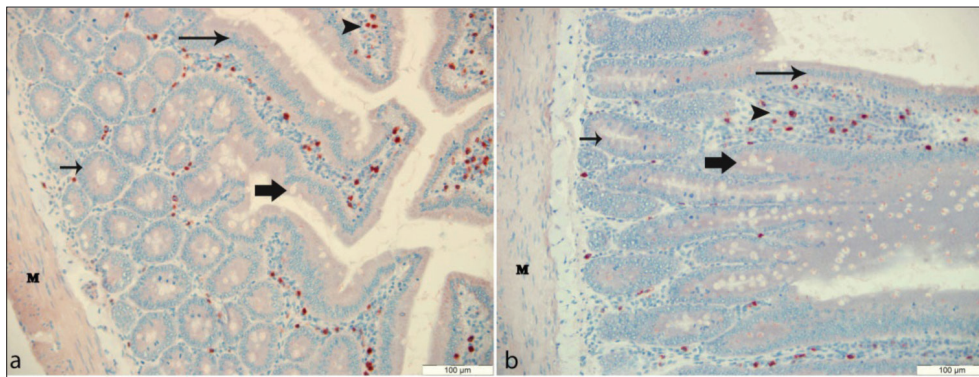


Fig 2. COX-2 immunoreactivity in rat duodenum. **a:** Experimental group, **b:** control group, Villus epithelial cell (long arrow), goblet cell (thick arrows), crypt epithelial cell (short arrow), smooth muscle cell (M), connective tissue cell (arrow head). Immunohistochemistry, Bar: 100 µm

Şekil 2. Rat duodenumunda COX-2 immünoreaktivitesi. **a:** Deney grubu, **b:** kontrol grubu, Villus epitel hücreleri (uzun ok), goblet hücresi (kalın ok), kript epitel hücresi (kısa ok), düz kas hücresi (M). İmmünohistokimya, Bar: 100 µm

cells of experimental group and moderate reaction was remarkable in connective tissue cells of control group. While moderate reaction was observed in smooth muscle cells in experimental groups, slight reaction was determined in smooth muscle cells in control group (Fig. 2, Table 2).

TGFβ-1 Immunoreactivity in Duodenum

While intensive cytoplasmic reaction was observed

in villus epithelial cells and in crypt epithelial cells of experimental group, slight cytoplasmic reaction was observed in villus epithelial cells and in crypt epithelial cells of control group. No reaction was determined goblet cells of all groups. While moderate reaction was determined in smooth muscle cells of experimental group, slight reaction was observed in smooth muscle cells of control group (Fig. 3, Table 3).

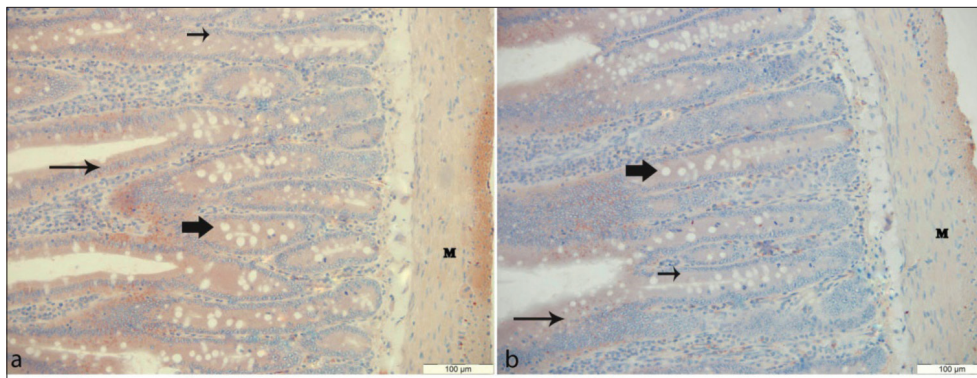


Fig 3. TGF β -1 immunoreactivity in rat duodenum. **a:** Experimental group, **b:** control group, Villus epithelial cell (long arrow), goblet cell (thick arrows), crypt epithelial cell (short arrow), smooth muscle cell (M). Immunohistochemistry, Bar: 100 μ m

Şekil 3. Rat duodenumunda TGF β -1 immünoreaktivitesi. **a:** Deney grubu, **b:** kontrol grubu, Villus epitel hücreleri (uzun ok), goblet hücreleri (kalın ok), kript epitel hücreleri (kısa ok), düz kas hücreleri (M). İmmünohistokimya, Bar: 100 μ m

DISCUSSION

Pain is the body's message that something is wrong in the system. These issues of pain are not diseases of themselves, but are symptoms of a dysfunction in associated structures [24]. Capsaicin belongs to group of analgesic substances [4,5,25]. This effect of capsaicin was found to function by preventing substance P, which is expressed in non-myelinated nerve fibers involved in carrying pain sensation from periphery to the center, from reaching the brain [26]. Because of this feature of capsaicin, it was predicted to be used in the treatment of arthritis, mild pains, as well as neuropathic pains following chemotherapy and sclerosis application [3].

COX expression has focused on pathological samples [3]. COX-1 is a constitutive enzyme and has a homeostatic role in gastrointestinal mucosa protection. COX-2 isoenzyme, frequently undetectable in most normal tissues, but quickly induced by inflammatory factors [13,27,28]. COX-2 selective agents were first approved for the treatment of acute and chronic pains and indications exist for the treatment of osteoarthritis, rheumatoid arthritis and a variety of musculoskeletal disorders [29,30].

In our study, COX-1 and COX-2 secretion was found to increase in capsaicin treated group. The findings support the view that capsaicin has a role in healing and reducing pains by both preventing pains sense from reaching the brain and increasing the release of COX-1 and COX-2.

In contrast to COX-1, it is generally believed that COX-2 is not present in most normal tissues, with the exception of the brain [31], kidney [32], and female reproductive system [33]. However, some previous studies have detected COX-2 in other normal tissues [34-41]. In our study, in addition to the aforementioned studies, the presence of COX-2 expression was detected in the duodenal tissue in both the control group and capsaicin treated group.

Expression of COX-1 was found mostly in blood vessels, connective tissue cells, smooth muscle cells, platelets and only rarely in parenchymal cells. In contrast, COX-2 was found predominantly in parenchymal cells, and only occasionally in resident inflammatory cells, connective tissue cells, endothelial cells and smooth muscle cells. Also, expression of COX-1 was greater than the expression of COX-2 in the small intestine [40]. In our study, COX-1 and COX-2 secretion was detected in similar cells (villus and crypt epithelial cells, smooth muscle cells). In addition, COX-2 was also identified in connective tissue cells unlike COX-1. In the study, COX-1 reaction intensity was seen to be more compared to COX-2 in cells with similar [40] reactions.

TGF- β is a multifunctional growth factor that influences growth and differentiation in many cell types [42] and modulation of cell growth, apoptosis and differentiation of intestinal epithelial cells [43,44]. TGF- β protein has been demonstrated villus and crypt epithelial cells in small intestine [17,18,45]. Besides the studies mentioned in our study, TGF β -1 secretion was found in villus and crypt epithelial cells in addition muscle tissue cells.

Capsaicin application has been expressed to increase TGF β release in various tissues [7,8]. However, no study was found in the literature regarding the effect of capsaicin application on TGF β -1 release in the duodenum. Bakir and Sarı [6] stated that capsaicin application increases the release of PDGF-C and PDGFR- α in villus, crypt epithelial cells, goblet cells and muscle cells of the duodenum. In our study, capsaicin application was also determined to increase the release of TGF β -1 in villus and crypt epithelial cells, and muscle tissue cells in duodenum.

As a result of our study in which we immunohistochemically investigated COX-1, COX-2 and TGF β -1 secretion in duodenum tissue of capsaicin treated rats, it was seen that capsaicin application increases the release of COX-1 that has a regulatory role in the gastrointestinal

tract, COX-2 that has regulatory role and functions in pathological and inflammatory conditions and TGF β -1 that has positive effects on growth and development.

REFERENCES

- Lembeck F:** Columbus, capsicum and capsaicin: Past, present and future. *Acta Physiol Hung*, 69, 265-273, 1987.
- Szalasi A, Blumberg PM:** Vanilloid (capsaicin) receptors and mechanisms. *Pharmacol Rev*, 51, 159-211, 1999.
- Başak S, Dikicioglu E, Turgutan S, Sarierler M:** Early and late effects of capsaicin pretreatment in otitis media with effusion. *Otol Neurotol*, 26, 344-350, 2005.
- Caterina MJ, Leffler A, Malmberg AB, Martin WJ, Trafton J, Petersen - Zeitz KR, Kdtzenburg M, Basbaum AI, Julius D:** Impaired nociception and pain sensation in mice lacking the capsaicin receptor. *Science*, 288, 306-313, 2000. DOI: 10.1126/science.288.5464.306
- Erdost H, Ozfiliz N, Ozgüden OS, Ilhan T, Ozer A:** Expression of a capsaicin reseptor (VRI) in the testis of mice after an application of capsaicin. *Bull Vet Inst Pulaway*, 51, 649-653, 2007.
- Bakır B, Sarı EK:** Immunohistochemical distribution of platelet derived growth factor-c and platelet derived growth factor receptor-alpha in small intestine of rats treated with capsaicin. *Turk J Vet Anim Sci*, 39, 160-167, 2015. DOI: 10.3906/vet-1405-24
- Nur G, Nazlı M, Yıldız SE:** Immunohistochemical localization of transforming growth factor beta 2 and gene expression using real-time PCR in capsaicin-administered rat testis during puberty. *Turk J Vet Anim Sci*, 38, 377-382, 2014. DOI: 10.3906/vet-1302-16
- Yıldız SE, Nazlı M, Nur G:** Immunohistochemical distribution and gene expression of transforming growth factor alpha in ovarian tissue of rats treated with capsaicin in puberty. *Turk J Med Sci*, 43, 326-332, 2013. DOI: 10.3906/sag-1205-120
- Smith WL, Garavito RM, Dewitt DL:** Prostaglandin endoperoxide H synthases (Cyclooxygenases) -1 and -2. *J Biol Chem*, 271, 331-357, 1996. DOI: 10.1074/jbc.271.52.33157
- Vane JR, Bakhlel YS, Botting RM:** Cyclooxygenases-1 and -2. *Annu Rev Pharmacol Toxicol*, 38, 97-120, 1998. DOI: 10.1146/annurev.pharmtox.38.1.97
- Williams CS, Dubois RN:** Prostaglandin endoperoxide synthase: Why two isoforms? *Am J Physiol*, 270, 393-400, 1996.
- Singer II, Kawka DW, Schloemann S:** Cyclooxygenase-2 is induced in colonic epithelial cells in inflammatory bowel disease. *Gastroenterology*, 115, 297-306, 1998. DOI: 10.1016/S0016-5085(98)70196-9
- Warner T, Mitchell JA:** Cyclooxygenases: New forms, new inhibitors, and lessons from the clinic. *FASEB J*, 18, 790-804, 2004.
- Wang F, Shi R, Zhao L:** Expression and significance of TGF- β 1 and VEGF in formation of new blood vessels after rabbit corneal suture. *Recent Adv Ophthalmol*, 28, 96-99, 2008.
- Ohtomo K, Ebihara N, Matsuda A, Tokura T, Funaki T, Murakami A:** Role of TGF- β 1 in tissue eosinophilia associated with vernal keratoconjunctivitis. *Experimental Eye Res*, 91, 748-754, 2010. DOI: 10.1016/j.exer.2010.08.025
- Powell DW, Mifflin RC, Valentich JD, Crowe SE, Saade JI, West AB:** Myofibroblasts, paracrine cells important in health and disease. *Am J Physiol*, 277, C1-C19, 1999.
- Barnard JA, Beauchamp RD, Coffey RJ, Moses HL:** Regulation of intestinal epithelial cell growth by transforming growth factor type β . *Proc Natl Acad Sci*, 86, 1578-1582, 1989.
- Barnard JA, Warwick GJ, Gold LI:** Localization of transforming growth factor β isoforms in the normal murine small intestine and colon. *Gastroenterology*, 105, 67-73, 1993.
- Harada N, Okajima, Arai M, Kurihara H, Nagata N:** Administration of capsaicin and isoflavone promotes hair growth by increasing insulin-like growth factor-I production in mice and in humans with alopecia. *Growth horm IGF res*, 17, 408-415, 2007.
- Habib A, Bernard M, Lebre C, Creminon B, Esposito A, Tedgui J, Maclouf J:** Regulation of the expression of cyclooxygenase-2 by nitric oxide in rat peritoneal macrophages. *J Immunol*, 158, 38-45, 1997.
- Hoffman C:** COX-2 in brain and spinal cord-implications for therapeutic use. *Curr Med Chem*, 7, 1113-1120, 2000.
- Moran C, Morales L, Razo RS, Apolonio J, Quiroz U, Chavira R, Dominguez R:** Effects of sensorial denervation induced by capsaicin injection at birth or on day three of life, on puberty, induced ovulation and pregnancy. *Life Sci*, 73, 2113-2125, 2003. DOI: 10.1016/S0024-3205(03)00598-8
- Tütüncü S, Özfiliz N:** Distribution of the vanilloid (capsaicin) receptor type 1 in the capsaicin treated rat ovaries on different sexual development periods. *Rev Méd Vét*, 162, 460-467, 2011.
- Eccleston C:** Role of psychology in pain management. *Br J Anaesth*, 87, 144-152, 2001. DOI: 10.1093/bja/87.1.144
- Yoshimura M, Yonehara N, Ito T, Kawai Y, Tamura T:** Effects of topically applied capsaicin cream on neurogenic inflammation and thermal sensitivity in rats. *Jpn J Pharmacol*, 82, 116-121, 2000.
- Shure D, Senior RM, Griffin GL, Deuel TF:** PDGF-AA homodimers are potent chemoattractants for fibro blast and neutrophils, and for monocytes activated by lymphocytes or cytokines. *Biochem Biophys Res Commun*, 186, 1510-1514, 1994. DOI: 10.1016/S0006-291X(05)81577-3
- Dannenberg AJ, Altorki NK, Boyle JO, Dang C, Howe LR, Weskler BB, Subbaramaiah K:** Cyclooxygenase-2: A pharmacological target for the prevention of cancer. *Lancet Oncol*, 2, 544-551, 2001. DOI: 10.1016/S1470-2045(01)00488-0
- Van Rees BP, Ristimaki A:** Cyclooxygenase-2 in carcinogenesis of the gastrointestinal tract. *Scand J Gastroenterol*, 36, 897-903, 2001.
- Flower RJ:** Drugs which inhibit prostaglandin biosynthesis. *Pharmacol Rev*, 26, 33-67, 1974.
- Sinatra R:** Role of COX-2 inhibitors in the evolution of acute pain management. *J Pain Symptom Manage*, 24, S18-S27, 2002. DOI: 10.1016/S0885-3924(02)00410-4
- Yermakowa A, O'banion MK:** Cyclooxygenases in the central nervous system: Implications for treatment of neurological disorders. *Curr Pharm Des*, 6, 1755-1776, 2000. DOI: 10.2174/1381612003398672
- Harris RC, Beyer MD:** Physiological regulation of cyclooxygenase-2 in the kidney. *Am J Physiol Renal Physiol*, 281, 1-11, 2001.
- Sirois J, Sayasith K, Brown KA, Stock AE, Bouchard N, Dore M:** Cyclooxygenase-2 and its role in ovulation: A 2004 account. *Human Reprod Update*, 17, 373-385, 2006. DOI: 10.1093/humupd/dmh032
- Asano K, Lilly CM, Drazen JM:** Prostaglandin G/H synthase-2 is the constitutive and dominant isoform in cultured human lung epithelial cells. *Am J Physiol*, 271, L126-L131, 1996.
- Fornai M, Blandizzi C, Colucco R:** Role of cyclooxygenase-1 and -2 in the modulation of neuromuscular functions in the distal colon of humans and mice. *Gut*, 54, 608-616, 2005.
- O'neil GP, Ford-Hudchinson AW:** Expression of mRNA for cyclooxygenase-1 and cyclooxygenase-2 in human tissues. *FEBS Lett*, 330, 156-160, 1993. DOI: 10.1016/0014-5793(93)80263-T
- Robertson RP:** Dominance of cyclooxygenase-2 in the regulation of pancreatic islet prostaglandin synthesis. *Diabetes*, 47, 1379-1383, 1998. DOI: 10.2337/diabetes.47.9.1379
- Sano H, Kawahito Y, Wilder RL:** Expression of cyclooxygenase-1 and -2 in human colorectal cancer. *Cancer Res*, 55, 3785-3789, 1995.
- Yasojima K, Schwab C, Mcgeer EG, Mcgeer PL:** Distribution of cyclooxygenase-1 and cyclooxygenase-2 mRNAs and proteins in human brain and peripheral organs. *Brain Res*, 830, 226-236, 1998. DOI: 10.1016/S0006-8993(99)01389-X
- Zidar N, Odar K, Glavak D, Jer'se M, Zupanc T, Stajer D:** Cyclooxygenase in normal human tissues - is COX-1 really a constitutive isoform, and COX-2 an inducible isoform? *J Cell Mol Med*, 13, 3753-3763, 2009. DOI: 10.1111/j.1582-4934.2008.00430.x

41. Zimmerman KC, Sarbia M, Schror K, Weber AA: Constitutive cyclooxygenase-2 expression in healthy human and rabbit gastric mucosa. *Mol Pharmacol*, 54, 536-534, 1998. DOI: 10.1124/mol.54.3.536

42. Miller DA, Lee A, Matsui Y, Chen EY, Moses HL, Derynck R: Complementary DNA cloning of the murine transforming growth factor- β 3 (TGF- β 3) precursor and the comparative expression of TGF- β 3 and TGF- β 1 messenger RNA in murine embryos and adult tissues. *Mol Endocrinol*, 3, 1926-1934, 1989. DOI: 10.1210/mend-3-12-1926

43. Fujiwara T, Stolker JM, Watanabe T, Rashid A, Longo P, Eshleman JR, Booker S, Lynch HT, Jass JR, Green JS, Kim H, Jen J,

Vogelstein B, Hamilton SR: Accumulated clonal genetic alterations in familial and sporadic colorectal carcinomas with widespread instability in microsatellite sequences. *Am J Pathol*, 153, 1063-1078, 1998. DOI: 10.1016/S0002-9440(10)65651-9

44. Markowitz D, Roberts B: Tumor suppressor activity of the TGF-beta pathway in human cancers. *Cytokine Growth Factor Rev*, 7, 93-102, 1997. DOI: 10.1016/1359-6101(96)00001-9

45. Koyama S, Podolsky DK: Differential expression of transforming growth factors α and β in rat intestinal epithelial cells. *J Clin Invest*, 83, 1768-1773, 1989. DOI: 10.1172/JCI114080