

Mesenchymal Tumors of the Prostate

Prostatin Mezenkimal Tümörleri

Meltem Öznur

Namık Kemal University Faculty of Medicine, Department of Pathology, Tekirdağ, Türkiye

Introduction

Mesenchymal tumors of the prostate are seen relatively rare in comparison with epithelial tumors and constitute less than 1% of all tumors (1). Despite they are seen rarely, there are great numbers of lesions in the differential diagnosis of mesenchymal tumors. Since mesenchymal tumors of the prostate are seen rarely, pathologists have very limited experience in this regard. Additionally, mesenchymal tumors show morphologically significant overlap with epithelial tumors causing problem particularly in the differential diagnosis of spindle cell mesenchymal tumors and they frequently require ancillary methods for accurate diagnosis.

Patients are mostly middle-aged and older and they generally present to hospital with symptoms of nonspecific urinary system obstruction. Besides, hematuria and rectal distension may be the admission symptoms as well. Prostate abnormality can be observed during examination, and increased serum prostate-specific antigen can be detected. Any of these symptoms and findings may not be a specific clinical finding of mesenchymal tumors. Imaging methods are not always reliable to identify the nature of the lesion. Well-circumscribed lesions may not always be benign, for example some prostatic sarcomas show well circumscribed growth pattern. Infiltrative-circumscribed lesions are not always malignant tumors; some mesenchymal tumors, such as inflammatory myofibroblastic tumors (IMTs), are infiltrative-circumscribed in spite of benign nature.

Biopsy is necessary for diagnosis. However, diagnosis is difficult in cases where a very limited part of the tumor is sampled at transurethral resection or needle biopsy. Stromal tumors of uncertain malignant potential (STUMP) containing, especially, mesenchymal as well as epithelial components, may not be noticed and they may be diagnosed as benign prostate tissue

or tumors containing pure spindle cell components can be mixed with stromal hyperplasia. There are numerous subtypes of mesenchymal tumors and the most commonly used categorization is the World Health Organization classification. This classification is summarized in Table 1 (2). Morphological and immunohistochemical characteristics of mesenchymal tumors of the prostate are given in Table 2 and 3.

Prostatic Stromal Tumors

Since histological patterns of tumors originating from the specialized prostatic stroma show wide spectrum, these tumors are classified into two different categories as prostatic STUMP and stromal sarcoma for making predictions about biological behavior and for treatment planning (3). Less than 100 cases of STUMP, which has been described by several names, such as atypical stromal hyperplasia, cystic epithelial-stromal tumor and phylloides, has been reported in the literature (3,4,5,6). STUMPs

Table 1. World Health Organization classification of mesenchymal tumors of the prostate

Stromal tumor of uncertain malignant potential
Stromal sarcoma
Leiomyosarcoma
Rhabdomyosarcoma
Leiomyoma
Angiosarcoma
Synovial sarcoma
Inflammatory myofibroblastic tumor
Osteosarcoma
Undifferentiated pleomorphic sarcoma
Solitary fibrous tumor
Solitary fibrous tumor, malignant
Haemangioma
Granular cell tumor

Correspondence: Meltem Öznur MD, Namık Kemal University Faculty of Medicine, Department of Pathology, Tekirdağ, Türkiye
Phone: +90 533 203 76 08 **E-mail:** meloznur@gmail.com **ORCID-ID:** orcid.org/0000-0002-6396-3168
Received: 18.02.2018 **Accepted:** 01.03.2018

Cite this article as: Öznur M. Mesenchymal Tumors of the Prostate. J Urol Surg 2018;5(1):59-62

©Copyright 2018 by the Association of Urological Surgery / Journal of Urological Surgery published by Galenos Publishing House.



have been reported to occur between the ages of 27 and 83 years with a peak incidence between 6th and 7th decades. They can be in the white, tan, solid or solid-cystic pattern (Figure 1) and up to 15 cm in size. STUMPs have been classified into four histologic patterns. The first pattern contains hypercellular stroma showing degenerative atypia with benign glands; the second pattern contains bland, fusiform stromal cells with eosinophilic cytoplasm with benign glands; the third pattern contains benign phylloides tumor-like hypercellular stroma with cytologically atypical/non-atypical benign glands and; the fourth pattern contains bland stromal cells in myxoid stroma without prostate glands (Figure 2). Recently, Sadimin and Epstein (7) described a novel round cell pattern. It shows CD34 (+), vimentin (+), progesterone (+), S100 (-) and C-kit (-) staining patterns, immunohistochemically. A large proportion of STUMPs has atypia and may imitate malignant

lesions such as stromal sarcoma. However, absence of atypical mitosis and presence of degenerative appearance of atypical nuclei with benign prostate glands help distinguish it from malignant tumors. STUMP is typically indolent, and generally cured with complete resection (3,8). However, as sarcomatoid differentiation may occur rarely, close follow-up is required in cases where complete resection is not possible (1,3).

Prostatic stromal sarcoma (PSS) is a rare malignant neoplasm originating from specialized stromal prostatic cells. Less than 40 cases of PSS have been reported in the literature (1). PSS has been reported to occur between the ages of 25 and 86 years. Half of the cases were under 50 years of age. PSS may arise *de novo* or it may develop from a previous STUMP (5). Macroscopically, PSS is a tan-white, solid, fleshy tumor 2-18

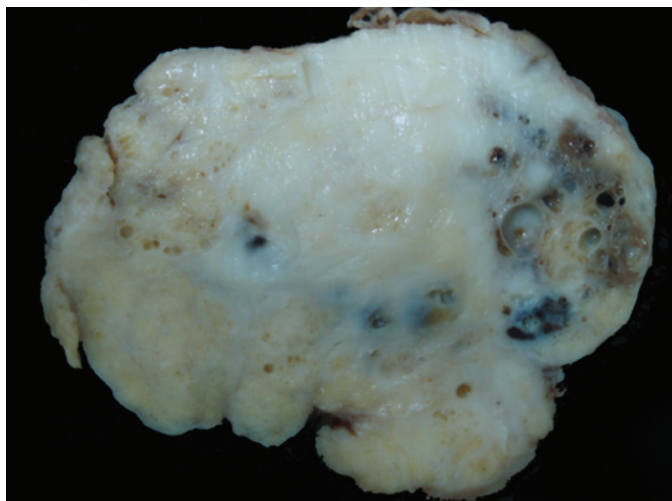


Figure 1. White-tan and solid-cystic pattern, well circumscribed stromal tumors of uncertain malignant potential

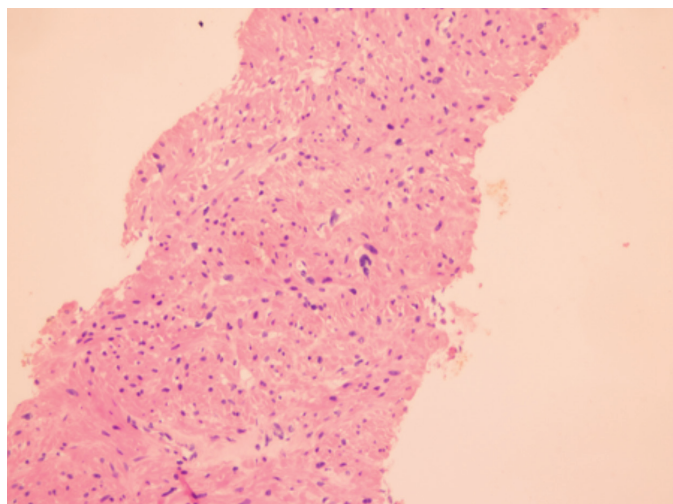


Figure 2. High magnification of a stromal tumors of uncertain malignant potential shows degenerative-appearing spindle cells in hypercellular stroma without glands

Table 2. Morphologic features of mesenchymal tumors of the prostate

	Morphological characteristic
STUMP	Four patterns: (1) Hypercellular stroma showing degenerative atypia with benign glands, (2) bland fusiform-shaped stromal cells with eosinophilic cytoplasm with benign glands, (3) benign phylloides tumor-like hypercellular stroma with cytologic atypical/non-atypical benign glands, (4) bland stromal cells in myxoid stroma without prostate glands
PSS	Hypercellularity, necrosis, cytologic atypia and mitosis; it is classified as low-grade and high-grade according to mitotic index and the degree of necrosis and atypia
Leiomyoma	Well-organized circumscribed crossing fascicles lacking mitotic activity and with little to no atypia
Leiomyosarcoma	Crossing fascicular structures showing mitoses, cytologic atypia, and necrosis
IMT	Uniform, reactive myofibroblasts on a loose zone with variable a level of inflammation and extravasation of red blood cells
SFT	Haphazard, patternless pattern, bland spindle cells, absence of mitosis, ropy collagen/hyalinizing deposits, myxoid changes and edema and sclerosis in the stroma
GIST	Fascicular growth pattern, bland spindle cells, perinuclear vacuoles. Some of the cases may show malignant features
RMS	Small round cells with variable eosinophilic cytoplasm, occasional elongated/strap cells, and, commonly, a myxoid background

STUMP: Stromal tumors of uncertain malign potential, PSS: Prostatic stromal sarcoma, IMT: Inflammatory myofibroblastic tumor, SFT: Solitary fibrous tumor, GIST: Gastrointestinal stromal tumor, RMS: Rhabdomyosarcoma

Table 3. Immunohistochemical features of mesenchymal tumors of the prostate

	SMA	Desmin	Myogenin	CD34	PgR	CD117	Pankeratin	ALK	S100	STAT6
STUMP	-/+	-/+	-	+	+	-	-	-	-	-
PSS	-/+	-/+	-	+	+	-	-	-	-	-
SMT	+	+	-	-	-	-	-/+	-	-	-
IMT	+	+	-	-	-	-	-/+	+	-	-
SFT	-/+	-	-	+	+/-	-	-	-	-	+
GIST	+/-	+/-	-	+	-	+	-	-	-	-
RMS	+	+	+	-	-	-	-	-	-	-
NT	-	-	-	-	-	-	-	-	+	-

STUMP: Stromal tumors of uncertain malign potential, PSS: Prostatic stromal sarcoma, SMT: Smooth muscle tumors, IMT: Inflammatory myofibroblastic tumor, SFT: Solitary fibrous tumor, GIST: Gastrointestinal stromal tumor, RMS: Rhabdomyosarcoma, NT: Neural tumors, SMA: Smooth muscle actin, PgR: Progesterone receptor, ALK: Anaplastic lymphoma kinase, STAT6: Signal transduction and activation of transcription 6

cm in size. Microscopically, it is similar to STUMP. Unlike STUMP, it exhibits marked increased cellularity, stromal cellular atypia, mitosis (which may be in atypical forms), and necrosis. The most common patterns are storiform, epithelioid, fibrosarcomatous, or patternless pattern. Less frequently, it consists of malignant phyllodes tumor-like hypercellular stroma and leaf-like glands. Its PSS storiform cell component consists of one or more of the followings: hypercellularity, cytologic atypia, mitotic figure and necrosis. It shows CD34 (+), vimentin (+), progesterone (+), S100 (-) and C-kit (-) staining pattern, immunohistochemically. In addition, PSSs are divided into two subgroups as low- and high-grade. High-grade tumors include moderate-evident cytologic atypia, hypercellularity, increased mitotic activity and necrosis. Low-grade PSSs are local invasive and high-grade ones metastasize mostly to the lung and bone, and usually require complete resection and adjuvant therapy (5).

Leiomyoma

Leiomyoma is seen rarely and less than 100 cases have been reported in the literature (9). Microscopically, they are non-atypical or less atypical tumors consisting of well-circumscribed crossing fascicular structures and having no mitotic activity. They are between 1 and 12 cm in size. Immunohistochemically, It differs from STUMP and gastrointestinal stromal tumor (GIST) by its smooth muscle actin (SMA) (+), desmin (+), C-kit (-) and CD34 (-) staining pattern.

Leiomyosarcoma

It is the most common sarcoma in the prostate in adults in the 5th to 8th decades of life (2,9). It is seen as poor-circumscribed infiltrative nodules between 1 and 25 cm in diameter. They are tumors composed of crossing-fascicular structures and they show mitosis, cytologic atypia and necrosis at high level. Immunohistochemically, it differs from other high-grade sarcomas by its SMA (+), desmin (+), h-caldesmon (+) S100 (-), C-kit (-) and CD34 (-) staining pattern. The clinical course of leiomyosarcomas is characterized by multiple recurrences and

pulmonary metastasis. Most patients die within 3-4 years of diagnosis (2).

Gastrointestinal Stromal Tumor

GISTs develop from the rectum or perirectal region and keep the prostate as a secondary site by infiltrating or compressing. Although GISTs occur in the gastrointestinal system, small numbers of prostatic GISTs have been reported in the literature (10,11). They contain perinuclear vacuoles in fascicular growth pattern and consist of storiform and epithelioid cells. Immunohistochemically, they differ from other mesenchymal tumors by CD34 (+), C-kit (+), discovered on GIST-1 (+), desmin (+/-), SMA (+/-), CD31 (-) and S100 (-) staining. Since their response to imatinib treatment is very good, correct diagnosis is very important.

Rhabdomyosarcoma

It is the most common soft tissue sarcoma in children. It has been reported very rarely in adulthood (2,12). They are tumors composed of small round cells with scant cytoplasm and variable numbers of eosinophilic small round cells, and elongated cells with occasionally variable eosinophilic cytoplasm on a frequent myxoid zone. Immunohistochemically, they differ from other tumors by myogenic differentiation 1 (+), myogenin (+), desmin (+) myoglobin (+), muscle specific actin (+), keratin (-) and terminal deoxynucleotidyl transferase (-) staining pattern. They respond well to multimodality treatment in childhood, but metastasis occurs even if complete resection is performed. Approximately half of adults die within 2 years due to the disease (12).

Inflammatory Myofibroblastic Tumor

IMTs have been described by several names such as post-operative spindle cell nodules in the literature (13). Morphology, molecular features and clinical behavior of the lesions, which develop as *de novo* or after a lower genitourinary tract procedure, are similar. IMT has been reported to affect adults between the ages of 42 and 67 years. Most of them are smaller

than 1 cm in size. They are tumors composed of uniform, reactive myofibroblasts on a loose zone with variable level of inflammation and extravasation of red blood cells. It shows vimentin (+), anaplastic lymphoma kinase-1 (+), calponin (+/-), SMA (+/-), CD34 (-), C-kit (-), keratin (-) and S100 (-) staining patterns. Although many cases of incomplete resections have been reported, they behave in a benign fashion and there is one reported case of metastasis in the literature (8).

Solitary Fibrous Tumor

Solitary fibrous tumor (SFT) is a rare storiform cell neoplasia, which is seen on the pleura and peritoneum. The first reported case of SFT involving the prostate was one of 5 tumors in the lower urinary tract in 2000 year (14). Up to now, 20 cases of SFT involving the prostate have been reported (8). It has been reported that patients with prostatic SFT were between the ages of 21 and 75 years and the lesions were measured 2-14 cm in size. Microscopically, it is composed of storiform cells that do not form any pattern. The classical histological feature of these tumors is the "irregular order" appearance. It also contains thick collagen bands and hyalinizing vessels in the form of distinctly branched, deer horn. Immunohistochemically, it differs from other mesenchymal tumors by its CD34 (+), signal transduction and activation of transcription 6 (+), aldehyde dehydrogenase 1 (+), desmin (-), SMA (-), CD31 (-), S100 (-) and C-kit (-) staining pattern (15). Although most of the SFT show benign features, some of these tumors have malign characters which show high mitotic activity (greater than 4/10 high power fields), mild and evident nuclear pleomorphism, increased cellularity, necrotic or hemorrhagic areas. Four cases have been reported so far in the literature (16,17).

Other Lesions

Mesenchymal tumors which are not specific for prostate such as angiosarcoma, synovial sarcoma, osteosarcoma, undifferentiated pleomorphic sarcoma, haemangioma, granular cell tumor and neural tumors have been reported as rare cases (2).

Conclusion

Despite the fact that mesenchymal tumors of the prostate constitute less than 1% of all tumors, their differential diagnosis is difficult and includes a broad spectrum of conditions. For this reason, it is important that clinical and radiological findings are reported to pathologists and adequate biopsy specimens are obtained. In spite of all these, the differential diagnosis of mesenchymal tumors may be problematic and ancillary methods may be needed for accurate diagnosis.

Acknowledgements

Special thanks to Prof. Dr. Kutsal Yörükoğlu for redaction and the figures.

Keywords: Prostate, Mesenchymal tumor, Differential diagnosis

Anahtar Kelimeler: Prostat, Mezenkimal tümör, Ayırıcı tanı

Ethics

Peer-review: Externally peer-reviewed.

Financial Disclosure: The author declared that this study received no financial support.

References

1. Mc Kenney JK. Mesenchymal tumors of the prostate. *Mod Pathol* 2018;31:133-142.
2. Chevillet J, Algaba F, Epstein JI, Lopez-Beltran A. In: Moch H. WHO classification of tumours of the urinary system and male genital organs. 4th ed. Lyon: the International Agency for Research on Cancer press, 2016, pp 175-177.
3. Gaudin PB, Rosai J, Epstein JI. Sarcomas and related proliferative lesions of specialized prostatic stroma: a clinicopathologic study of 22 cases. *Am J Surg Pathol* 1998;22:148-162.
4. Bostwick DG, Hossain D, Qian J, Neumann RM, Yang P, Young RH, di Sant'agnese PA, Jones EC. Phyllodes tumor of the prostate: long-term followup study of 23 cases. *J Urol* 2004;172:894-899.
5. Herawi M, Epstein JI. Specialized stromal tumors of the prostate: a clinicopathologic study of 50 cases. *Am J Surg Pathol* 2006;30:694-704.
6. Fukuhara S, Matsuoka Y, Hanafusa T, Nakayama M, Takayama H, Tsujihata M, Nonomura N, Okuyama A. A case report of prostatic stromal tumor of uncertain malignant potential (STUMP). *Hinyokika Kyo* 2008;54:377-381.
7. Sadimin ET, Epstein JI. Round cell pattern of prostatic stromal tumor of uncertain malignant potential: a subtle newly recognized variant. *Hum Pathol* 2016;52:68-73.
8. Hansel DE, Herawi M, Montgomery E, Epstein JI. Spindle cell lesions of the adult prostate. *Mod Pathol* 2007;20:148-158.
9. Tavora F, Kryvenko ON, Epstein JI. Mesenchymal tumours of the bladder and prostate: an update. *Pathology* 2013;45:104-115.
10. Herawi M, Montgomery EA, Epstein JI. Gastrointestinal stromal tumors (GIST) on prostate needle biopsy: A clinicopathologic study of 8 cases. *Am J Surg Pathol* 2006;30:1389-1395.
11. Xu H, Liu C, Chen Y, Gu M, Cai Z, Chen Q, Wang Z. Diagnosis and treatment of gastrointestinal stromal tumor extending to prostate: A case report and literature review. *Medicine (Baltimore)* 2016;95:e5439.
12. Raney RB, Anderson JR, Barr FG, Donaldson SS, Pappo AS, Qualman SJ, Wiener ES, Maurer HM, Crist WM. Rhabdomyosarcoma and undifferentiated sarcoma in the first two decades of life: a selective review of intergroup rhabdomyosarcoma study group experience and rationale for Intergroup Rhabdomyosarcoma Study V. *J Pediatr Hematol Oncol* 2001;23:215-220.
13. Huang WL, Ro JY, Grignon DJ, Swanson D, Ordonez NG, Ayala AG. Postoperative spindle cell nodule of the prostate and bladder. *J Urol* 1990;143:824-826.
14. Westra WH, Grenko RT, Epstein J. Solitary fibrous tumor of the lower urogenital tract: a report of five cases involving the seminal vesicles, urinary bladder, and prostate. *Hum Pathol* 2000;31:63-68.
15. Guner G, Bishop JA, Bezerra SM, Taheri D, Zahavi DJ, Mendoza Rodriguez MA, Sharma R, Epstein JI, Netto GJ. The utility of STAT6 and ALDH1 expression in the differential diagnosis of solitary fibrous tumor versus prostate-specific stromal neoplasms. *Hum Pathol* 2016;54:184-188.
16. Vodovnik A, Rogawski K, Bolton JF. A case of malignant solitary fibrous tumor of the prostate. *Pathol Int* 2005;55:807-8.
17. Herawi M, Epstein JI. Solitary fibrous tumor on needle biopsy and transurethral resection of the prostate: a clinicopathologic study of 13 cases. *Am J Surg Pathol* 2007;31:870-6.