



Surgical approach in adrenal incidentalomas: Report of thirteen cases and review of the literature

Hasan Erdem¹, Süleyman Çetinkünar¹, Faruk Kuyucu², Hakan Erçil², Mustafa Görür¹, Selim Sözen³

ABSTRACT

Objective: The rate of adrenal incidentalomas detected in routine diagnostic imaging techniques is approximately 4-7%. Although the lesions are generally benign, carcinoma and functional adenomas can be diagnosed with careful clinic and laboratory evaluation.

Material and Methods: Data of 13 patients who underwent surgery for an adrenal mass between January 2010-June 2014 were analyzed retrospectively.

Results: Seven (54%) patients were male, 6 (46%) were female, and the mean age was 38.2. The clinical diagnosis was pheochromocytoma in 5 patients (38.4%), non-functional adenoma in 5 (38.4), and metastatic lesion, Cushing syndrome, and adrenal carcinoma each in one patient (7.6%). Conventional open adrenalectomy was performed in 8 patients, while 5 patients underwent laparoscopic adrenalectomy.

Conclusion: Adrenal incidentalomas should be carefully evaluated for hormonal activity even if asymptomatic, and non-functional lesions should be considered as suspicious-for-malignancy. Laparoscopic adrenalectomy has become the gold standard for patients with a mass less than 6 cm, and without infiltration to adjacent organs.

Keywords: Adrenal mass, incidentaloma, surgery, laparoscopy

INTRODUCTION

Adrenal tumors that are incidentally detected while investigating a disease that is potentially related to the adrenal gland such as obesity and hypertension are termed incidentaloma. Although when evaluated retrospectively it has been determined that these patients had complaints due to the adrenal mass or hormonal activity, they were included in the incidentaloma group for being identified coincidentally (1, 2). Most incidentaloma lesions are benign and do not require treatment (3). Further tests may reveal a non-functioning mass as well as subclinical Cushing's disease, pheochromocytoma, aldosterone-secreting adenoma and metastatic lesions (4). In recent years, particularly with the widespread use of ultrasonography (US), computed tomography (CT) and magnetic resonance imaging (MRI), there has been a marked increase in the overall incidence of incidentalomas. Adrenal incidentalomas should primarily be assessed in terms of the lesion's hormonal activity and malignant potential (5, 6).

MATERIAL AND METHODS

In this study, the diagnostic methods and surgical treatment of 13 patients who were admitted for incidentally diagnosed adrenal lesions while being investigated for other reasons to the General Surgery and Urology Clinics between January 2010-June 2014 were retrospectively evaluated and presented. The study was approved by the Adana Numune Training and Research Hospital local ethics committee. Data regarding age, sex, symptoms at diagnosis, laboratory examination, additional medical history, operative and postoperative findings were recorded. In the preoperative endocrine evaluation; 24-hour urine metanephrine, vanillylmandelic acid, and normetanephrine levels were measured in all patients for pheochromocytoma. In patients with suspicion of Cushing's syndrome, 1 g dexamethasone suppression test was performed according to basal ACTH and cortisol levels. In addition, in hypertensive patients, plasma aldosterone concentration, plasma renin activity and aldosterone to renin ratio were investigated for primary hyperaldosteronism after regulating the antihypertensive treatment in a way not to affect the renin-angiotensin-aldosterone system. Ultrasound, CT and MRI were utilized as radiologic examinations. The lesion size, location, homogeneity, and invasion to surrounding structures were assessed. Lesions with suspicion of malignancy were further evaluated by MRI to identify their relation to the surrounding tissue. Postoperative histopathologic evaluation of the specimens and postoperative complications were recorded.

¹Clinic of General Surgery, Adana Numune Training and Research Hospital, Adana, Turkey

²Clinic of Urology, Adana Numune Training and Research Hospital, Adana, Turkey

³Department of General Surgery, Namık Kemal University School of Medicine, Tekirdağ, Turkey

Address for Correspondence

Hasan Erdem

e-mail:

drhasanerdem@yahoo.com

Received: 28.11.2014

Accepted: 12.02.2015

Available Online Date: 18.08.2015

©Copyright 2016
by Turkish Surgical Association
Available online at
www.ulusalcerrahidergisi.org

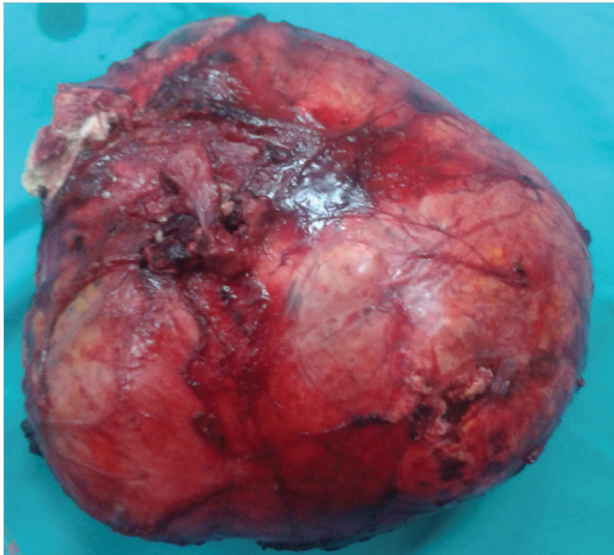


Figure 1. Case 2, right adrenal carcinoma resection specimen of 24x21x9 cm in size

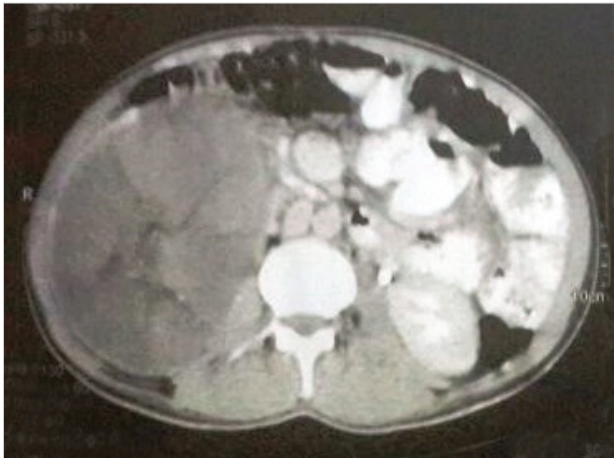


Figure 2. Case 2, right adrenal gland mass on computed tomography

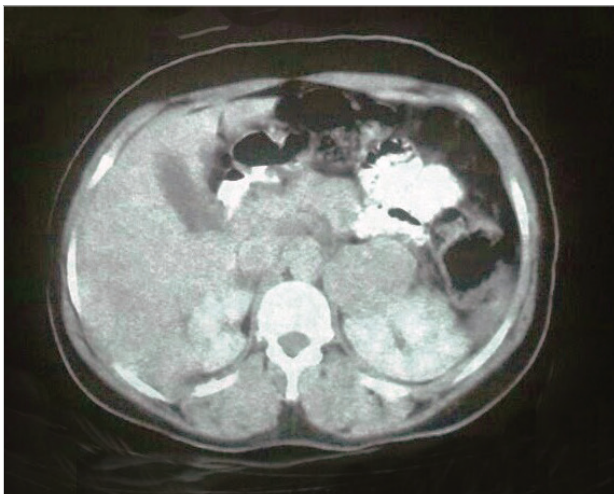


Figure 3. Case 12, metastatic adrenal carcinoma, computed tomography view

RESULTS

A total of 13 patients were operated on for an adrenal mass between January 2010-June 2014. Seven of these cases (54%) were male and 6 (46%) were female, with a mean age of 38.2

years. Clinically 5 patients (38.4%) were diagnosed with pheochromocytoma, 5 patients (38.4%) with nonfunctional adenoma, 1 patient (7.6%) with metastatic lesion, 1 patient (7.6%) with Cushing's syndrome, and 1 patient (7.6%) with adrenal carcinoma. Histologic examination of the 5 patients with non-functional adenoma revealed adrenocortical carcinoma, myelolipoma, cystic lymphangioma, adrenocortical adenoma, and ganglioneuroma each in one patient (7.6%).

Nine patients underwent surgery with laparotomy, and 4 with laparoscopy. Five patients had right-sided (38.4%), and 8 had left-sided adrenal lesions (61.5%). In none of the cases laparoscopic surgery was converted to open surgery. We had no operative mortality. One patient developed surgical site infection as the only morbidity.

DISCUSSION

The majority of adrenal incidentaloma patients are hormonally inactive. However, all lesions should be evaluated in terms of hormonal activity or local invasion. The detailed evaluation may reveal lesions that requires surgery such as adrenocortical carcinoma, pheochromocytoma, primary aldosteronism, and Cushing's syndrome, or benign nonfunctioning adenoma that requires clinical follow-up (3, 7, 8).

One of the most challenging issues is the decision for surgery in patients with hormonally inactive adrenal incidentalomas. Adrenal incidentalomas smaller than 4 cm are usually considered to be benign and follow-up is recommended for such lesions. Hormonal inactive lesions between four to six cm can be followed-up if they appear homogenous on imaging, and can be treated with surgery if there is an increase in size or detection of irregular borders on follow-up. The likelihood of malignancy is higher in lesions with rapid growth, with findings of surrounding tissue invasion, or those with heterogeneity. Surgery should be planned in all lesions greater than six cm in size (9). Incidentalomas should be planned for surgical treatment regardless of their size if they are hormonally active (8-10). The most common hormonally active tumors are pheochromocytomas (7, 11, 12).

Although the incidence of pheochromocytoma is 2-8/million, it constitutes 11-23% of adrenal incidentalomas. The classic triad refers to hypertensive attacks, flushing and headache, and these symptoms are present in only 40% of patients diagnosed with pheochromocytoma. Most patients remain asymptomatic. They are usually diagnosed incidentally or during procedures such as percutaneous biopsy or induction of anesthesia during surgery. Measurement of plasma metanephrine levels provide a diagnosis in suspected cases with 99% sensitivity and 89% specificity. Five of the herein presented cases had pheochromocytoma (11, 12). An adrenal mass was detected in all of these cases while investigating the etiology of hypertension, they were diagnosed with hormonal active adrenal tumors on additional biochemical tests, and thus were operated. Perhaps the most specific cases in adrenal surgery are those with pheochromocytoma (13, 14). Severe hypertensive episodes can occur during the operation due to excessive catecholamine discharge with tactile stimulation. Therefore, the operation should be carried out in coordination with the anesthesia team, and dissection should be interrupted on any hypertensive episodes and should be continued only after the blood pressure is under control. The adrenal veins should be

Table 1. Demographic, clinical and pathologic findings of 13 cases operated on for adrenal mass

Case	Age/ gender	Symptom	Location	Lesion size	Treatment	Pathologic diagnosis
1	21 F	Back pain	Right	7 x 4 x 4	Open adrenalectomy	Ganglioneuroma
2	28 M	Intraabdominal mass	Right	24 x 21 x 9	Open adrenalectomy	Adrenal carcinoma
3	17 M	Hypertension	Left	7.5 x 6.5 x 5.5	Open adrenalectomy	Pheochromocytoma
4	33 F	Hypertension	Left	6 x 5 x 3	Laparoscopic adrenalectomy	Pheochromocytoma
5	56 F	Hypertension	Left	13 x 9 x 8	Open adrenalectomy	Pheochromocytoma
6	40 F	Back pain	Left	5 x 4 x 4	Open adrenalectomy	Adrenocortical adenoma
7	26 F	Back pain	Right	8 x 7 x 5	Open adrenalectomy	Myelolipoma
8	47 M	Back pain	Left	12 x 13 x 8	Open adrenalectomy	Adrenocortical carcinoma
9	14 M	Asymptomatic	Right	6 x 4 x 2	Open adrenalectomy	Cystic lymphangioma
10	11 M	Cushing's syndrome	Left	4.5 x 4.5 x 2	Open adrenalectomy	Adrenocortical adenoma
11	68 F	Hypertension	Left	4 x 4 x 3	Laparoscopic adrenalectomy	Pheochromocytoma
12	72 M	PET-CT control	Left	4 x 3 x 3	Laparoscopic adrenalectomy	Lung carcinoma metastasis
13	64 M	Hypertension	Right	5 x 4 x 4	Laparoscopic adrenalectomy	Pheochromocytoma

ligated first in order to minimize catecholamine discharge. It should also be kept in mind that rebound hypotension episodes may develop in the postoperative period in patients with pheochromocytoma (9, 15-17).

Adrenal myelolipoma is a rare, non-functional benign tumor composed of fat and mature hemopoietic tissues. Usually small and asymptomatic, they can present with chronic pain as size increases (18, 19). Although the traditional approach in myelolipomas is conservative follow-up, Ramirez et al. (19) recommend surgical treatment for lesions larger than 6 cm since it may lead to complications such as chronic pain, rupture and hemorrhage. One of the presented cases was a myelolipoma of the right adrenal gland 8 x 7 x 5 cm in size, which resulted in back pain, and was successfully removed by laparotomy.

Adrenal carcinoma is an extremely rare malignancy with an incidence of 1/1 million. Approximately 50% of these tumors are functional and secrete glucocorticoid, mineralocorticoid, estrogen and androgen. The most prominent feature of adrenal carcinomas is their capability of growing to large sizes (20-22). Two of the present cases are adrenal cortical carcinomas with dimensions of 24 x 21 x 9 cm and 13 x 12 x 8 cm (Figure 1, 2).

Metastatic adrenal lesions are seen more often than primary adrenal carcinoma. Lung carcinoma, breast carcinoma, some kidney tumors, and malignant melanoma are reported to metastasize frequently to the adrenal gland (23). Surgery for adrenal metastatic tumors should be carried out in accordance with oncologic principles. During the operation, if possible, en-bloc resection should be performed and surrounding tissues should be evaluated for invasion. Surgical exploration or laparoscopic excision of the tumor can be planned depending on lesion size and the surgeon's experience. It is stated that open surgery is more effective in large, locally invasive lesions and those with retroperitoneal lymphadenopathy (23-25).

One of the presented cases was a patient who has been treated for small cell lung carcinoma, and whose 3rd year follow-

up revealed a left-sided adrenal mass that was diagnosed as metastatic adrenal carcinoma on further investigations. The 4-cm mass without local invasion and retroperitoneal lymphadenopathy was removed by laparoscopy (Figure 3).

Adrenalectomy can be performed using either the laparoscopic or conventional method. It has been reported that conventional intervention would be more appropriate in centers with insufficient expertise and in cases with large tumor size. Problems related to wound infection, recovery time, and image acquisition are more frequent in conventional methods as compared to laparoscopy in obese patients (8, 10). In the conventional procedure; transperitoneal, retroperitoneal, lateral transperitoneal (Chevron incision), lateral (extraperitoneal), posterior (extraperitoneal), thoraco-abdominal (transpleural/transperitoneal) approaches are being used, and it is reported that a midline incision is more appropriate for bilateral adrenalectomy (9, 26, 27).

Laparoscopy in adrenal tumors can be performed either transperitoneally or retroperitoneally. The transperitoneal approach provides a wider exposure and better assessment of the relationship with other abdominal organs. It is also possible to intervene on either side in cases with bilateral adrenal masses. Postoperative gastrointestinal functions are affected less in the retroperitoneal approach. But the possibility of injury to the abdominal organs due to limited angle of view is higher in the retroperitoneal approach (8, 26). In our clinic, laparoscopic surgery is a common procedure, and since the majority of our operations are performed with the transperitoneal approach other organs and tissues are evaluated best with this method. This is why, in all cases of laparoscopic adrenalectomy the transperitoneal approach was preferred.

CONCLUSION

Laparoscopic procedures can reliably be applied for the evaluation and the treatment of adrenal masses in appropriate cases, with technical advances and increasing experience in laparoscopic surgery.

Ethics Committee Approval: Ethics committee approval was received for this study from the ethics committee of Adana Numune Training and Research Hospital.

Informed Consent: In this study, since the data can not be used to identify patients' personal data, patient's consent was not required.

Peer-review: Externally peer-reviewed.

Author Contributions: Concept - H.E.; Design - H.E.; Supervision - H.E., S.S.; Funding - H.E., S.Ç.; Materials - F.K., H.E.Ç.; Data Collection and/or Processing - H.E., M.G.; Analysis and/or Interpretation - H.E., H.E.Ç., S.Ç., F.K.; Literature Review - H.E., F.K.; Writer - H.E.; Critical Review - F.K., H.E.Ç., S.Ç., S.S.

Conflict of Interest: No conflict of interest was declared by the authors.

Financial Disclosure: The authors declared that this study has received no financial support.

REFERENCES

1. Bovio S, Cataldi A, Reimondo G, Sperone P, Novello S, Berruti A, et al. Prevalence of adrenal incidentaloma in a contemporary computerized tomography series. *J Endocrinol Invest* 2006; 29: 298-302. [\[CrossRef\]](#)
2. Singh PK, Buch HN. Adrenal incidentaloma: evaluation and management. *J Clin Pathol* 2008; 61: 1168-1173. [\[CrossRef\]](#)
3. Kapoor A, Morris T, Rebello R. Guidelines for the management of the incidentally discovered adrenal mass. *Can Urol Assoc J* 2011; 5: 241-247. [\[CrossRef\]](#)
4. Gopan T, Remer E, Hamrahian AH. Evaluating and managing adrenal incidentalomas. *Cleve Clin J Med* 2006; 73: 561-568. [\[CrossRef\]](#)
5. Yoh T, Hosono M, Komeya Y, Im SW, Ashikaga R, Shimono T, et al. Quantitative evaluation of norcholesterol scintigraphy, CT attenuation value, and chemical-shift MR imaging for characterizing adrenal adenomas. *Ann Nucl Med* 2008; 22: 513-519. [\[CrossRef\]](#)
6. Aron D, Terzolo M, Cawood TJ. Adrenal incidentalomas. *Best Pract Res Clin Endocrinol Metab* 2012; 26: 69-82. [\[CrossRef\]](#)
7. Pedziwiatr M, Natkaniec M, Kisialewski M, Major P, Matlok M, Koldziej D, et al. Adrenal incidentalomas: should we operate on small tumors in the era of laparoscopy? *Int J Endocrinol* 2014; 2014: 658483.
8. Shi BB, Li HZ, Chen C, Rong S, Fan H, Wen J, et al. Differential diagnosis and laparoscopic treatment of adrenal pheochromocytoma and ganglioneuroma. *Chin Med J (Engl)* 2009; 122: 1790-1793.
9. Prager G, Heinz-Peer G, Passler C, Kaczirek K, Schindl M, Scheuba C, et al. Surgical strategy in adrenal masses. *Eur J Radiol* 2002; 41: 70-77. [\[CrossRef\]](#)
10. Zeiger MA, Siegelman SS, Hamrahian AH. Medical and surgical evaluation and treatment of adrenal incidentalomas. *J Clin Endocrinol Metab* 2011; 96: 2004-2015. [\[CrossRef\]](#)
11. Cheah WK, Clark OH, Horn JK, Siperstein AE, Duh QY. Laparoscopic adrenalectomy for pheochromocytoma. *World J Surg* 2002; 26: 1048-1051. [\[CrossRef\]](#)
12. Sutton MG, Sheps SG, Lie JT. Prevalence of clinically unsuspected pheochromocytoma. Review of a 50-year autopsy series. *Mayo Clin Proc* 1981; 56: 354-360.
13. Kitano M, Komasa N, Sawai T, Minami T. Successful anesthetic management of a patient with giant pheochromocytoma using high-dose landiolol hydrochloride. *Masui* 2014; 63: 898-900.
14. Knuttgen D, Wappler F. Anaesthesia for patients with phaeochromocytoma - specifics, potential complications and drug strategies. *Anesthesiol Intensivmed Notfallmed Schmerzther* 2008; 43: 20-27.
15. Badri M, Gibbons AV, Popii V, Yih D, Cohen-Stein DL, Patel SM. Perioperative management of a patient with a nonresectable pheochromocytoma. *Endocr Pract* 2013; 19: e74-76. [\[CrossRef\]](#)
16. Faria EF, Andreoni C, Krebs RK, Nascimento H, Goldman SM, Kater C, et al. Advances in pheochromocytoma management in the era of laparoscopy. *J Endourol* 2007; 21: 1303-1307. [\[CrossRef\]](#)
17. Szymanski FM, Karpinski G, Hryniewicz-Szymanska A, Filipiak KJ. Resistant hypertension in an obese patient with obvious obstructive sleep apnea and occult pheochromocytoma. *Can J Cardiol* 2012; 28: 397. [\[CrossRef\]](#)
18. Nabi J, Rafiq D, Authoy FN, Sofi GN. Incidental detection of adrenal myelolipoma: a case report and review of literature. *Case Rep Urol* 2013; 2013: 789481. [\[CrossRef\]](#)
19. Ramirez M, Misra S. Adrenal myelolipoma: To operate or not? A case report and review of the literature. *Int J Surg Case Rep* 2014; 5: 494-496. [\[CrossRef\]](#)
20. Munver R, Fromer DL, Watson RA, Sawczuk IS. Evaluation of the incidentally discovered adrenal mass. *Curr Urol Rep* 2004; 5: 73-77. [\[CrossRef\]](#)
21. Iacconi P, Bendinelli C, Miccoli P, Bernini GP. Re: A case of Cushing's syndrome due to adrenocortical carcinoma with recurrence 19 months after laparoscopic adrenalectomy. Re: A case of Cushing's syndrome due to adrenocortical carcinoma with recurrence 19 months after laparoscopic adrenalectomy. *J Urol* 1999; 161: 1580-1581. [\[CrossRef\]](#)
22. Lumachi F, Borsato S, Tregnaghi A, Marino F, Fassina A, Zucchetta P, et al. High risk of malignancy in patients with incidentally discovered adrenal masses: accuracy of adrenal imaging and image-guided fine-needle aspiration cytology. *Tumori* 2007; 93: 269-274.
23. Bendinelli C, Lucchi M, Buccianti P, Iacconi P, Angeletti CA, Miccoli P. Adrenal masses in non-small cell lung carcinoma patients: is there any role for laparoscopic procedures? *J Laparoendosc Adv Surg Tech A* 1998; 8: 119-124. [\[CrossRef\]](#)
24. Boland GW, Lee MJ, Gazelle GS, Halpern EF, McNicholas MM, Mueller PR. Characterization of adrenal masses using unenhanced CT: an analysis of the CT literature. *AJR Am J Roentgenol* 1998; 171: 201-204. [\[CrossRef\]](#)
25. Schteingart DE, Doherty GM, Gauger PG, Giordano TJ, Hammer GD, Korobkin M, et al. Management of patients with adrenal cancer: recommendations of an international consensus conference. *Endocr Relat Cancer* 2005; 12: 667-680. [\[CrossRef\]](#)
26. Bulus H, Uslu HY, Karakoyun R, Kocak S. Comparison of laparoscopic and open adrenalectomy. *Acta Chir Belg* 2013; 113: 203-207.
27. Mannelli M, Dralle H, Lenders JW. Perioperative management of pheochromocytoma/paraganglioma: is there a state of the art? *Horm Metab Res* 2012; 44: 373-378. [\[CrossRef\]](#)