

# Combined Treatment of Both Arterial and Deep Venous Thrombosis in a Young Adult with Antiphospholipid Syndrome: Case Report

## Antifosfolipid Sendromlu Genç Erkek Hastada Derin Ven Trombozu ve Arteriyel Trombozun Kombine Tedavisi

Selami GÜRKAN,<sup>a</sup>  
Özcan GÜR,<sup>a</sup>  
Serhat HÜSEYİN,<sup>b</sup>  
Volkan YÜKSEL,<sup>b</sup>  
Suat CANBAZ<sup>b</sup>

<sup>a</sup>Department of Cardiovascular Surgery,  
Namık Kemal University  
Faculty of Medicine, Tekirdağ

<sup>b</sup>Department of Cardiovascular Surgery,  
Trakya University Faculty of Medicine,  
Edirne

Geliş Tarihi/Received: 08.02.2013  
Kabul Tarihi/Accepted: 09.04.2013

Yazışma Adresi/Correspondence:  
Selami GÜRKAN  
Namık Kemal University  
Faculty of Medicine,  
Department of Cardiovascular Surgery,  
Tekirdağ,  
TÜRKİYE/TURKEY  
gurkancem@yahoo.com

**ABSTRACT** Antiphospholipid syndrome (APS) is an autoimmune hypercoagulability syndrome that induces a wide variety of thromboembolic events. Deep venous thrombosis is complicated by pulmonary embolism and infarction in 35% of cases. The clinical manifestations of the syndrome include venous and arterial thromboses and embolisms, disseminated large and small vessel thromboses with accompanying multiorgan ischemia and infarction, premature coronary artery disease, stroke and pregnancy losses. In this paper, we describe a rare case of both venous and arterial thromboembolic event in a 25-year-old young male age who had surgical treatment with medical treatment.

**Key Words:** Thrombosis; antiphospholipid syndrome; venous thrombosis

**ÖZET** Antifosfolipid sendromu değişik tromboembolik olaylara sebep olabilen, otoimmün hiperkoagülabilite sendromudur. Olguların %35'inde pulmoner emboli ve infarktla komplike olabilen derin ven trombozu görülebilir. Hastalığın klinik görünüşleri arasında; venöz ve arteriyel trombozlarla birlikte emboliler, multiorgan iskemisi ve infarktına neden olabilen küçük ve yaygın büyük damar trombozları, prematür koroner arter hastalığı, strok ve düşükler sayılabilir. Bu yazıda 25 yaşındaki genç erkek hastada görülen arteriyel ve venöz trombozu ile cerrahi ve medikal tedavi birlikteliğini sunduk

**Anahtar Kelimeler:** Tromboz; antifosfolipid sendromu; venöz tromboz

**Damar Cer Derg 2014;23(1):50-2**

Antiphospholipid syndrome (APS) is an autoimmune hypercoagulability syndrome that induces a wide variety of thromboembolic events. In the general population, APS is the most common acquired cause of hypercoagulability. Vascular complications have been diagnosed mainly by Doppler ultrasonography, computerized tomography (CT) or angiography.<sup>1</sup> Antiphospholipid antibodies are known to induce a prothrombotic state causing arterial and venous thromboembolism. There is a growing evidence regarding the interrelations of these antibodies and their mechanisms causing endothelium activation and hypercoagulation.<sup>2</sup> Sapporo classification criteria for the APS were defined in an international consensus conference to simplify the diagnosis.<sup>3</sup>

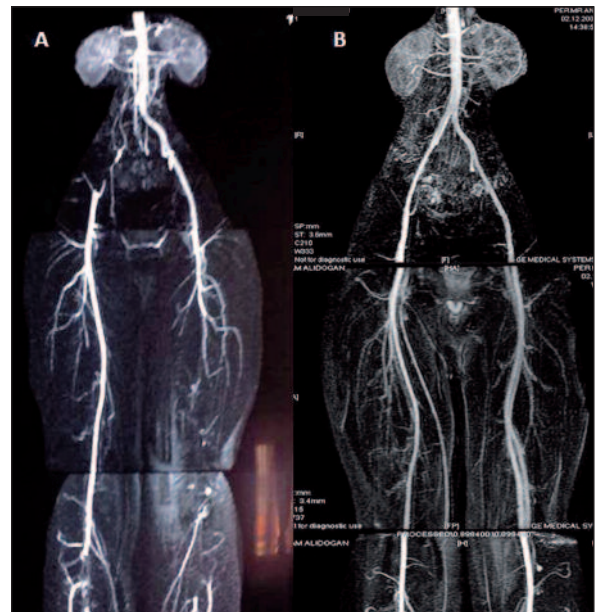
In this paper, we describe a rare case of venous and arterial thromboembolic event in a 25-year-old young male.

## CASE REPORT

A 25-year-old young male was admitted to our institution with subacute lower limb ischemia, necrosis of the distal phalanges of right foot and deep venous thrombosis of right lower extremity. He had history of intermittent claudication and swelling during the past two weeks and a Doppler ultrasonography showing deep venous thrombosis of right lower extremity. He had no family history of a clotting disorder. Upon admission, magnetic resonance angiography demonstrated total occlusion of right iliac, tibioperoneal trunk arteries and left superficial femoral and popliteal artery (Figure 1A). Screening for thrombophilia including activated protein C (APC) resistance, protein C, protein S, antithrombin III (ATIII) were within normal ranges and Factor V-Leiden mutation was negative. Furthermore, plasma dilute Russell's viper venom time (dRVVT) and lupus anticoagulant (LA) levels were positive at admission and at least six weeks apart. Anticardiolipin (aCL) antibody of IgG and IgM isotype in blood were negative both at admission and at six weeks control. Left suprarenal, right infrarenal and right femoral Fogarty catheter-thrombo-embolectomy operations were performed consecutively, accompanied by amputation of the necrotic toes. Postoperatively, the patient received intravenous unfractionated heparin (aPTT 50-70 s) and oral anticoagulation therapy was started with a target international normalized ratio (INR) range of 2.5-3.5. Control magnetic resonance angiography showed bilateral normal iliac and lower extremity arteries (Figure 1B).

## DISCUSSION

Antiphospholipid syndrome has recently drawn the attention of numerous clinicians because of its close relationship with thrombotic events.<sup>1</sup> Antiphospholipid syndrome is considered as an autoimmune disorder where vascular thrombosis and/or recurrent pregnancy pathologies occur in patients with laboratory evidence for antibodies against phospholipids.<sup>4</sup> The most frequently reported association with APS is deep venous thrombosis which is multiple and bilateral, affecting particu-



**FIGURE 1:** A) Magnetic resonance angiography of distal abdominal aorta and bilateral lower extremities in a patient with antiphospholipid syndrome. There is occlusion of the right iliac, tibioperoneal trunk arteries and left superficial femoral and popliteal arteries. B) Control magnetic resonance angiography showing that both iliac arteries and bilateral lower extremity arteries were normal.

larly lower limbs.<sup>5</sup> Deep venous thrombosis is also complicated by pulmonary embolism and infarction in 35% of cases. Recurrent thromboembolism can lead to pulmonary hypertension and clinical findings of right ventricular insufficiency. In addition, coexistence of pulmonary embolism and intracardiac thrombus can lead to sudden death.<sup>6</sup> The clinical manifestations of the syndrome include venous and arterial thromboses and embolisms, disseminated large and small vessel thromboses with accompanying multiorgan ischemia and infarction, premature coronary artery disease, stroke and pregnancy losses.<sup>7</sup> The diagnosis of APS is based on the presence of at least one clinical and one laboratory criteria as defined in Sapporo classification system.<sup>3</sup>

We did not investigate pulmonary embolism since the echocardiographic evaluation did not show any evidence of right ventricular failure or pulmonary hypertension, and there was no clinical signs for pulmonary embolism.

We report a rare condition in the literature where both arterial and venous thrombosis occurred in a young male patient who had intermittent

cladication and gangrenous necrosis at lower extremity with high plasma levels of dRVVT and LA without any evidence of connective tissue disease. Remarkably, aCL antibodies and  $\beta$ 2-GP-1 antibodies were not elevated.

The first evidence of large peripheral arterial occlusions in systemic lupus erythematosus patients appeared in 1960s.<sup>8</sup> During the following years, more studies on large arterial occlusions and gangrene in patients with APS were published. In addition, occlusions of the abdominal aorta in aPL positive patients were also observed.<sup>9,10</sup>

Shortell et al. reported in their study that antiphospholipid syndrome should be suspected in young, female nonsmokers with vascular disease, especially those with involvement of the upper extremity and premature graft failure.<sup>11</sup> Similar to this study, the case was young and a non-smoker, contrarily thrombosis occurred at the lower extremity.

Opinions concerning treatment of APS vary widely. The main treatment of APS is anticoagulant/antiaggregant medications. Corticosteroids may be useful in hematological manifestations (thrombocytopenia, hemolytic anemia and myelo-

pathy). Prevention of recurrent thrombosis is achieved by prolonged oral anticoagulation. Intensive therapy to a target INR higher than 3.0 is the most effective.<sup>12</sup> All patients with thrombosis associated with APS should undergo long-term (life-long) warfarin therapy.

In this case, anticoagulation with heparin was initiated at admission and consecutive Fogarty catheter-thrombo-embolectomies were performed successfully. Vena cava filter insertion before operation was not planned due to absence of clinical symptoms for pulmonary embolism and since this was an acute situation.

## CONCLUSION

In conclusion, we have reported an APS patient complicated by both arterial and venous thrombosis with gangrenous toes. We suppose that immediate surgical treatment in addition to long term anticoagulation may be justified for the patients with occlusive vascular disease in APS.

## Conflict of Interest

*Authors declared no conflict of interest or financial support.*

## REFERENCES

1. Khamashta MA, Cuadrado MJ, Mujic F, Taub NA, Hunt BJ, Hughes GR. The management of thrombosis in the antiphospholipid-antibody syndrome. *N Engl J Med* 1995;332(15):993-7.
2. Galli M, Barbui T. Antiphospholipid antibodies and thrombosis: strength of association. *Hematol J* 2003;4(3):180-6.
3. Robertson B, Greaves M. Antiphospholipid syndrome: an evolving story. *Blood Rev* 2006;20(4):201-12.
4. Mutlu LC, Türker G, Gülbaş G, Yıldırım Z, Aydoğdu İ. Nadir bir hemoptizi nedeni: antifosfolipid antikor sendromu. *Solunum Hastalıkları* 2004;15:43-6.
5. Hughes GR. The antiphospholipid syndrome: ten years on. *Lancet* 1993;342(8867):341-4.
6. Gündoğdu F, Ünlü Y, Barış N, Arslan S. Antiphospholipid antibody syndrome leading to massive pulmonary embolism and sudden death. *Arch Turk Soc Cardiol* 2008;36(7):467-9.
7. Rand JH. Molecular pathogenesis of the antiphospholipid syndrome. *Circ Res* 2002;90(1):29-37.
8. Alarcon Segovia D, Osmundson PJ. Peripheral vascular syndromes associated with systemic lupus erythematosus. *Ann Intern Med* 1965;62:907-19.
9. Bird AG, Lendrum R, Asherson RA, Hughes GR. Disseminated intravascular coagulation, antiphospholipid antibodies, and ischaemic necrosis of extremities. *Ann Rheum Dis* 1987;46(3):251-5.
10. Drew P, Asherson RA, Zuk RJ, Goodwin FJ, Hughes GR. Aortic occlusion in systemic lupus erythematosus associated with antiphospholipid antibodies. *Ann Rheum Dis* 1987;46(8):612-6.
11. Shortell CK, Ouriel K, Green RM, Condemni JJ, DeWeese JA. Vascular disease in the antiphospholipid syndrome: a comparison with the patient population with atherosclerosis. *J Vasc Surg* 1992;15(1):158-65.
12. Khamashta MA. Management of thrombosis in the antiphospholipid syndrome. Hughes' syndrome. London: Springer; 2000. p.391-6.