

CASE REPORT

Open Access



Ultrasound-guided erector spinae plane catheter for postoperative continuous analgesia in a patient undergoing pericardial window opening surgery for pericardial tamponade: a case report

Ayhan Şahin¹, Ahmet Gültekin¹, Selami Gürkan², Onur Baran^{3*}  and Cavidan Arar¹

Abstract

Background: Anesthetic management of pericardial tamponade is requiring full use of abilities for anesthesiologists because of associated cardiovascular problems inherent to this condition, with its associated comorbidities.

Case presentation: A 55-year-old man diagnosed with severe mitral insufficiency, asthma, diabetes, and pleural effusion in the lungs and pericardial effusion was scheduled for pericardial window opening surgery.

Conclusions: Due to compromised lung functions and asthma of the patient led to an anesthetic plan of ultrasound-guided erector spinae plane catheter placement for long-term continuous analgesia.

Keywords: Pericardial tamponade, Erector spinae plane block, Catheter, Asthma

Background

Anesthetic management of pericardial tamponade is requiring full use of abilities for anesthesiologists because of associated cardiovascular problems inherent to this condition, with its associated comorbidities. Erector spinae plane (ESP) block is recently described by Forero et al (Forero et al. 2016). Since then, this technique has been used in a wide variety of indications including postoperative analgesia, surgical anesthesia, and management of chronic pain (Altinpulluk et al. 2018).

Surgical drainage can be achieved by the creation of a subxiphoid pericardial window, or a small anterior thoracotomy using either an open or thoracoscopic approach or by the creation of a pericardial-peritoneal window (Grocott et al. 2011; O'Connor and Tuman 2010).

The ESP block is safe and simple to apply, compared with paravertebral blocks or thoracic epidural. ESP block prevents both visceral and somatic pain in several case

reports and studies in breast surgery (Bonvicini et al. 2017; Selvi and Tulgar 2019).

Here, we report a successful ESP block and catheter for postoperative analgesia in a patient who underwent pericardial window opening surgery.

A written informed consent was obtained from the patient.

Case presentation

A 55-year-old man (72 kg, 175 cm) was diagnosed with pericardial tamponade while being monitored in coronary intensive care unit (CCU) due to heart failure. In his medical history, he had asthma, type 2 diabetes, hypothyroidism, and coronary artery disease. The patient's American Society of Anesthesiologists Score was III. The patient was scheduled for pericardial window opening surgery (lateral thoracotomy approach) by our Department of Cardiovascular Surgery.

Unilateral ESP block and inserting of a catheter was planned for postoperative analgesia. Induction of anesthesia was performed using propofol 2 mg kg⁻¹, fentanyl 100 µg, and rocuronium 0.5 mg kg⁻¹. Anesthesia

* Correspondence: dronurban@hotmail.com

³Clinic of Anesthesiology and Reanimation, Palandöken State Hospital, Muratpaşa Mh. Yenişehir Cd. No: 35 Yakutiye, Erzurum, Turkey
Full list of author information is available at the end of the article

was maintained with 2% sevoflurane mixed with 50% oxygen and air following a successful intubation. ESP block and insertion of the catheter was performed in the prone position at T5 vertebral level using 8-MHz linear ultrasound probe (Esaote Mylab Six Ultrasound System Genoa, Italy) in sterile conditions. Firstly, the probe was located 3 cm lateral to the T1 spinous process and scanned through the T5 vertebra and trapezius, rhomboideus major, and erector spinae muscles were displayed superficial to the transverse process. An 18-gauge Tuohy needle (Braun Perifix, Germany) was inserted using in-plane technique at the level of T5 transverse process. When the tip of the needle reached and touched the T5 transverse process, 10 mL of 0.5% bupivacaine was administered after confirming the correct location by hydrodissection anterior to erector spinae muscle with 1–2 mL saline solution (Fig. 1). Then, the multi-orifice catheter was advanced through the Tuohy needle into the hydro-dissected area within the plane (Fig. 2). The tip of the catheter was left between T5 and T4 vertebra transverse processes with 3 cm part in the soft tissue. The catheter was secured using the instant skin adherence apparatus (Fig. 3). No complications occurred during and after the block procedure. A patient-controlled analgesia (PCA) device fastened to the catheter tip and adjusted for pacing 5 mL h^{-1} 0.25% bupivacaine.

During surgery, which included a semi-oblique incision in the fourth intercostal region, no complications such as severe hypotension or arrhythmia occurred. After 45 min of surgery, the patient was transferred to the postanesthesia care unit for close postoperative follow-up. The pain was measured using numeric rating scale (NRS) (“0” representing “no pain,” “10” representing “worst pain imaginable”), and it was < 2 in PACU. The patient’s modified Aldrete’s score was 10, and he was transferred to the general ward. He did not need any rescue analgesic postoperatively, and the catheter was withdrawn due to infection related concerns after 24 h.

In this case, a local anesthetic injection was applied unilaterally via a PCA device which includes 120 mL of 0.25% bupivacaine in total (5 mL per hour for 24 h). Although there is still not enough clear data over local analgesic dose in ESP block, De Cassai suggested 3.6 mL of local anesthetic for each targeted dermatome, and he proposed the application of high volume and low concentration formula for plane blocks (De Cassai and Tonetti 2018). Therefore, in this case, local anesthetics were diluted and used in a greater volume to reach the adequate spread of sensorial block. We did not observe any signs of neurotoxicity or cardiotoxicity in our patient during the treatment period.

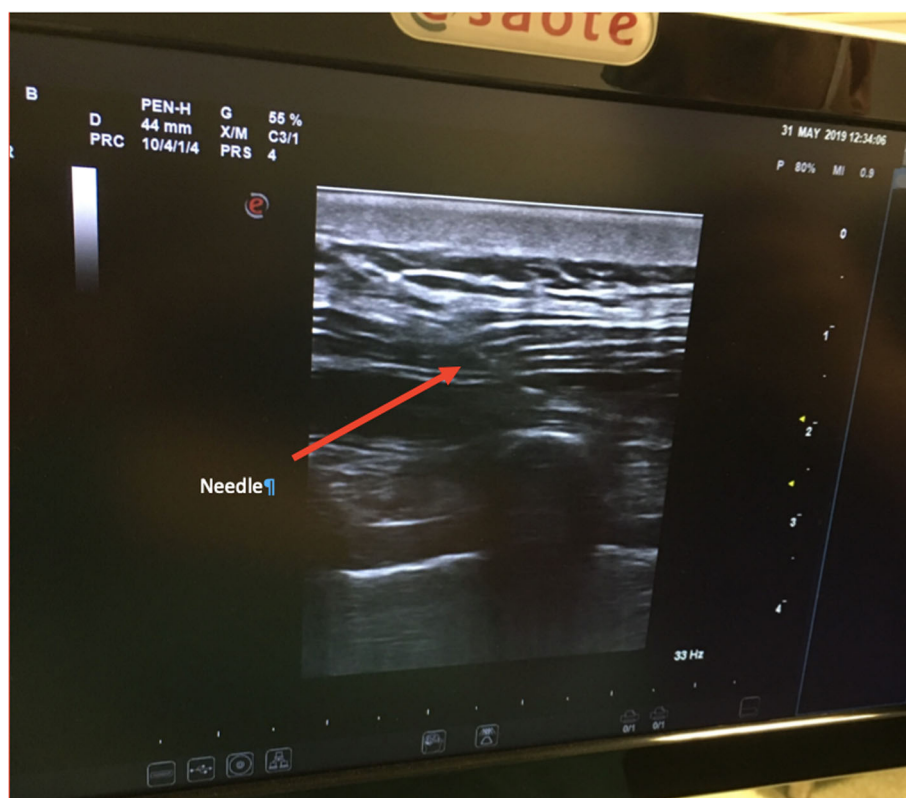


Fig. 1 Advancing of needle to the T5 transverse process

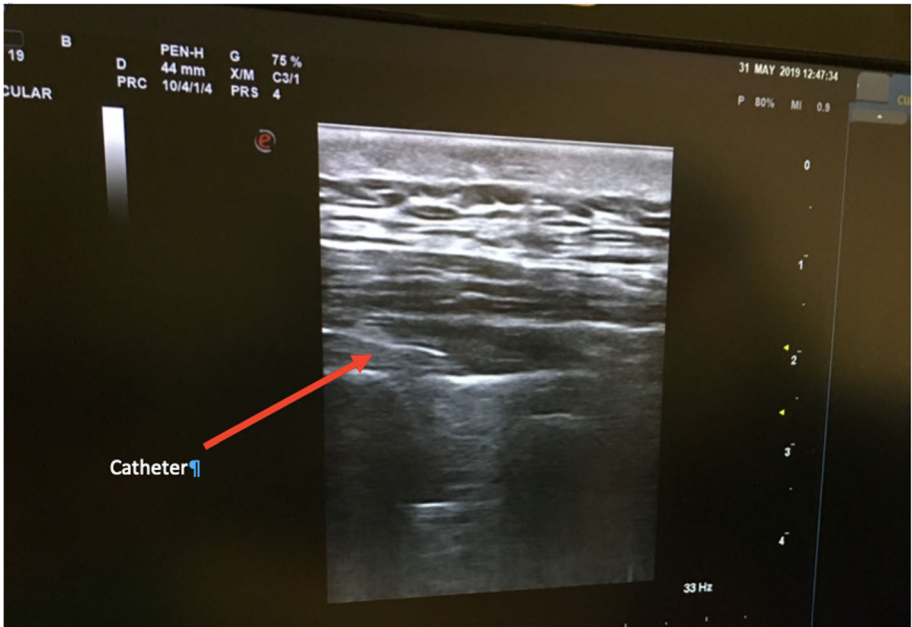

Fig. 2 Advancing of catheter in the erector spinae plane

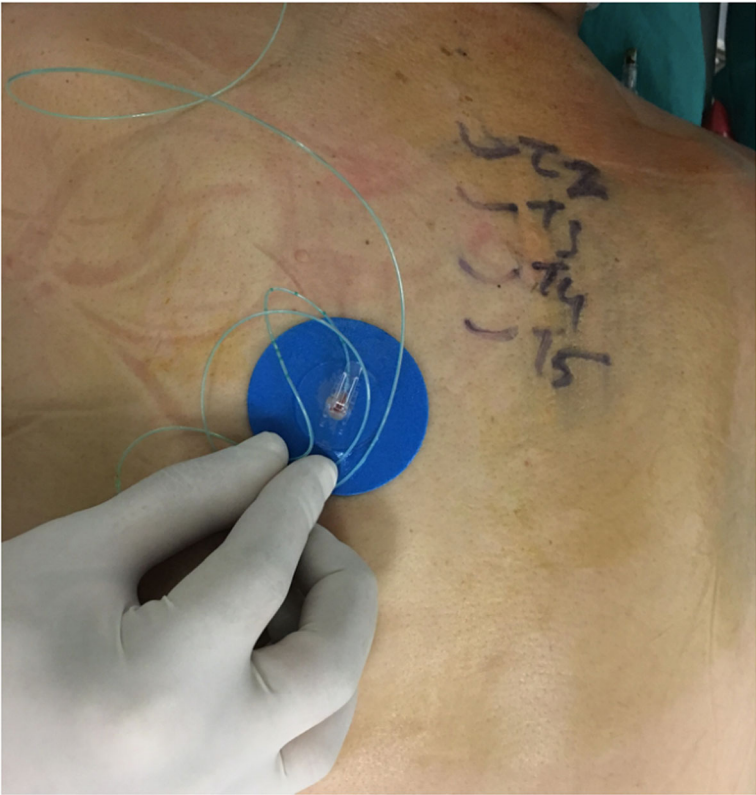

Fig. 3 The secured catheter with the instant skin adherence apparatus

Discussion

Successful ESP blocks have been used in major abdominal surgery and breast implant surgeries (Bonvicini et al. 2017; Restrepo-Garces et al. 2017). Although the mechanism of analgesic efficacy of ESP block remains unclear, previous cadaver models have demonstrated that deposition of local anesthetic deep (anterior) to the erector spinae muscle reaches the paravertebral space through connective tissues and ligaments (Chin et al. 2017). Radiological imaging of a cadaver model has shown that ESP leads to widespread sensory block between C7 and T8 when it is applied at the level of T5. This area was our target field for pericardial window opening surgery (lateral thoracotomy approach). We propose that ESP block may be an alternative and useful choice for postoperative analgesia in pericardial window opening surgery (lateral thoracotomy approach). Since ESP has an effect on the dorsal, ventral, and communicant ramus of spinal nerve roots, it is similar to paravertebral block or thoracic epidural block, without the complications attributed to these two major methods (Grocott et al. 2011). In addition, it is easy to perform in intubated patients with fewer complications because the needle insertion point is at a distant location to important anatomical structures especially to pleura.

Dyspnea is the most common presenting finding with cardiac tamponade (Gandhi et al. 2008). Medications trigger a minority of asthma attacks, but reactions can be serious. Postoperative pain can also trigger asthma attacks; therefore, impaired pulmonary functions after surgery may be worsened by postoperative pain, while effective analgesia can prevent respiratory complications (Xue et al. 1999). In another case report, Scimia et al. performed an ultrasound-guided ESP block in a patient undergoing video-assisted thoracoscopic lobectomy in which they placed a catheter for a continuous ESP block (Scimia et al. 2017). They removed the catheter on the third postoperative day and reported a sensory block at the T2 to T10 dermatomes which supplied good quality of analgesia. Wilson et al. performed a single-shot ESP block in a patient compromised respiratory function and reported that single-shot ESP block not only provided successful analgesia but it also improved the arterial blood gas and chest radiographs of the patient (Wilson et al. 2018).

Conclusions

In conclusion, a preemptive ESP block with continuous analgesia in a patient undergoing pericardial window opening surgery for pericardial tamponade may provide effective analgesia as a part of multimodal analgesia treatment for compromised lung functions.

Abbreviations

ESP: Erector spinae plane; ICU: Intensive care unit; NRS: Numeric rating scale; PCA: Patient-controlled analgesia

Acknowledgements

None

Authors' contributions

AS helped in the searching of the literature. AG helped in the methodology. SG helped in the editing. OB helped in the writing of the manuscript. CA helped in the basic outline of the manuscript. The authors read and approved the final manuscript.

Funding

None

Availability of data and materials

The data was extracted from the medical records file of the patient and the materials are being used which were available in our set up with valid reasons.

Ethics approval and consent to participate

Ethical approval is not required for publication of isolated case reports.

Consent for publication

Written permission/consent for reproduction of images of the patient for the purpose of publication in an educational medical journal was obtained from the patient.

Competing interests

The authors declare that they have no competing interests.

Author details

¹Department of Anesthesiology and Reanimation, Medical Faculty of Namik Kemal University, Tekirdağ, Turkey. ²Department of Cardiovascular Surgery, Medical Faculty of Namik Kemal University, Tekirdağ, Turkey. ³Clinic of Anesthesiology and Reanimation, Palandöken State Hospital, Muratpaşa Mh. Yenişehir Cd. No: 35 Yakutiye, Erzurum, Turkey.

Received: 17 September 2019 Accepted: 17 February 2020

Published online: 27 February 2020

References

- Altinpulluk EY, Simón DG, Fajardo-Pérez M (2018) Erector spinae plane block for analgesia after lower segment caesarean section: case report. *Revista Española de Anestesiología y Reanimación (English Edition)* 65:284–286 %@ 2341–1929
- Bonvicini D, Giacomazzi A, Pizzirani E (2017) Use of the ultrasound-guided erector spinae plane block in breast surgery. *Minerva Anestesiologica* 83:1111–1112 %@ 0375–9393
- Chin KJ, Malhas L, Perlas A (2017) The erector spinae plane block provides visceral abdominal analgesia in bariatric surgery: a report of 3 cases. *Reg Anesth Pain Med* 42:372–376 %@ 1098–7339
- De Cassai A, Tonetti T (2018) Local anesthetic spread during erector spinae plane block. *J Clin Anesth* 48:60–62 %@ 1873–4529
- Forero M, Adhikary SD, Lopez H, Tsui C, Chin KJ (2016) The erector spinae plane block: a novel analgesic technique in thoracic neuropathic pain. *Reg Anesth Pain Med* 41:621–627
- Gandhi S, Schneider A, Mohiuddin S et al (2008) Has the clinical presentation and clinician's index of suspicion of cardiac tamponade changed over the past decade? *Echocardiography* 25:237–241 %@ 0742–2822
- Grocott HP, Gulati H, Srinathan S, Mackensen GB (2011) Anesthesia and the patient with pericardial disease. *Can J Anaesth* 58:952–956 %@ 0832–610X
- O'Connor CJ, Tuman KJ (2010) The intraoperative management of patients with pericardial tamponade. *Anesthesiol Clin* 28:87–96
- Restrepo-Garces CE, Chin KJ, Suarez P, Diaz A (2017) Bilateral continuous erector spinae plane block contributes to effective postoperative analgesia after major open abdominal surgery: a case report. *A & A Case Rep* 9:319–321 %@ 2325–7237

- Scimia P, Ricci EB, Droghetti A, Fusco P (2017) The ultrasound-guided continuous erector spinae plane block for postoperative analgesia in video-assisted thoracoscopic lobectomy. *Reg Anesth Pain Med* 42:537 %@ 1098–7339
- Selvi O, Tulgar S (2019) Use of the ultrasound-guided erector spinae plane block in segmental mastectomy. *Turk J Anaesthesiol Reanim* 47:158–160
- Wilson JMB, Lohser J, Klaibert B (2018) Erector spinae plane block for postoperative rescue analgesia in thoracoscopic surgery. *J Cardiothorac Casc Anesth* 32:e5–e7 %@ 1053–0770
- Xue FS, Li BW, Zhang GS et al (1999) The influence of surgical sites on early postoperative hypoxemia in adults undergoing elective surgery. *Anesthe Analg* 88:213–219 %@ 0003–2999

Publisher's Note

Springer Nature remains neutral with regard to jurisdictional claims in published maps and institutional affiliations.

Submit your manuscript to a SpringerOpen[®] journal and benefit from:

- ▶ Convenient online submission
- ▶ Rigorous peer review
- ▶ Open access: articles freely available online
- ▶ High visibility within the field
- ▶ Retaining the copyright to your article

Submit your next manuscript at ▶ [springeropen.com](https://www.springeropen.com)
