

## Case Report

---

# Cutaneous Anthrax on the Upper Eyelid

Ekrem Celik<sup>a</sup> Tansu Gonen<sup>b</sup>

<sup>a</sup>Department of Ophthalmology, Tekirdag City Hospital, Tekirdag, Turkey; <sup>b</sup>Department of Ophthalmology, Tekirdag Namik Kemal University, Tekirdag, Turkey

## Keywords

*Bacillus anthracis* · Cutaneous anthrax · Upper eyelid

## Abstract

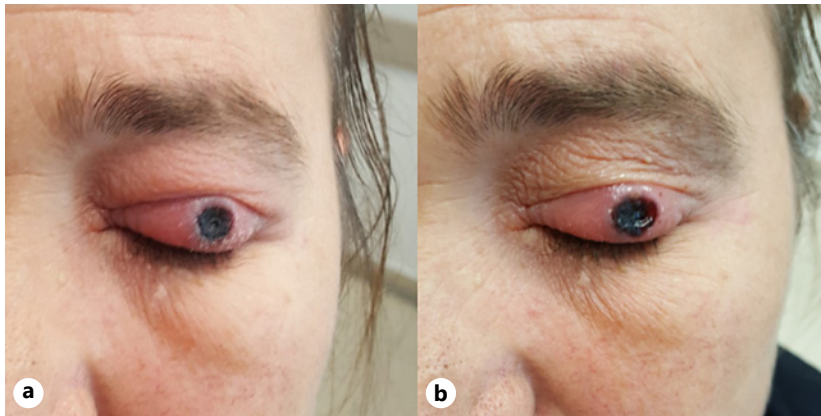
A 46-year-old female patient, who presented with a black, crusty lesion on the upper eyelid, was diagnosed with cutaneous anthrax after the detection of *Bacillus anthracis* in the skin culture. It was determined that the symptoms started after she cooked the meat she bought from a butcher. Anthrax is a disease that should be kept in mind in cutaneous infections even in isolated lesions, especially in endemic areas.

© 2021 The Author(s).

Published by S. Karger AG, Basel

## Introduction

Anthrax is an infection caused by *Bacillus anthracis*, a gram-positive rod, immotile, spore-forming bacterium. It is transmitted to humans from herbivores such as cattle, goats, and sheep. It usually presents with lung, intestinal, and cutaneous involvement [1, 2]. Although cutaneous anthrax is the most common form, accounting for about 95% of all anthrax species, eyelid involvement is a rare condition [3]. A painless papule surrounded by redness and edema develops on the skin after direct contact with the hand that comes into contact with contaminated food or an infected animal. The lesion then becomes a vesicle and ulcerates with bleeding and may cause necrosis and black scarring on the eyelid [4]. In this presentation, we aimed to discuss an isolated eyelid form of anthrax, which is endemic and can threaten public health.



**Fig. 1.** **a** In the first examination, redness, swelling, black eschar, and a crusty lesion on the left upper eyelid looks compatible with skin anthrax. **b** On the second day, the skin culture was taken again, but no growth was observed due to the use of antibiotics.

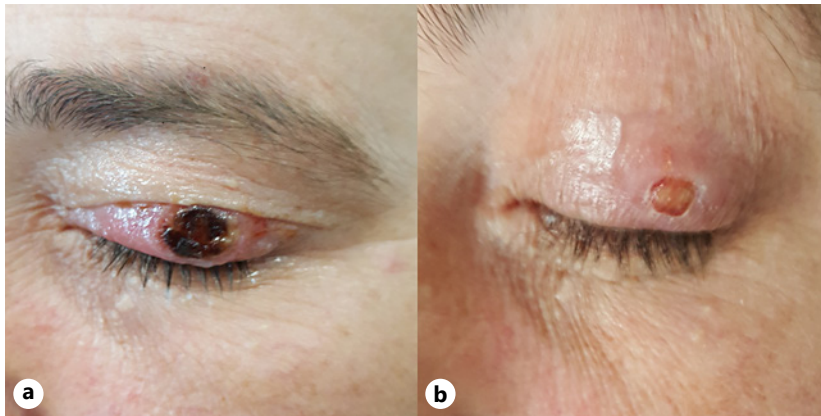
### Case Report

A 46-year-old female patient was referred to the clinic with a 1-cm-diameter round, blackish, ulcerated, and crusted surface lesion on the left upper eyelid that started 5 days ago. In the regional anthrax endemic period in 2018, the patient had contact with the meat she bought from a butcher and had no direct contact with an infected animal. Visual acuity was normal in both eyes, and there were no ophthalmic findings other than swelling, redness, and a black, dry ulcerated lesion on the upper eyelid (shown in Fig. 1a). Body temperature and hemogram values were within normal limits. There was no growth in the blood culture. Gram(+) bacilli compatible with *B. anthracis* were observed in Gram staining performed with the wound culture taken from the lesion. For oral treatment, ciprofloxacin 500 mg every 8 h and amoxicillin 875 mg + clavulanic acid 125 mg every 12 h were started. For topical treatment, chloramphenicol ointment was started twice daily. A slight increase in eyelid edema was observed 1 day after the treatment (shown in Fig. 1b). A sample was taken from the wound again on the second day, and this time no growth was observed due to antibiotic use. On the seventh day of treatment, healing zones were seen in the middle of the crust and on the intact skin border. Eyelid edema and redness regressed (shown in Fig. 2a). On the 16th day, the antibiotic treatment was stopped, based on signs of significant improvement in the lesion (shown in Fig. 2b).

### Discussion

*B. anthracis* is mostly transmitted by herbivorous animals due to its ability to survive in the soil for many years. Incidence is more common in farmers, butchers, veterinarians, shepherds, and farm workers. It can be transmitted by contact with contaminated meat or bones, hair, or skin of an infected animal or by breathing in air containing its spores [5]. Therefore, there are more rural case reports. On the contrary, in our case, indirect contamination occurred in urban life.

The main transmission mechanism is thought to be the contact of bacterial spores under the nail with the skin [2, 5, 6]. When cutaneous anthrax first starts, it presents with a slightly itchy, pink appearance. Later, a brown ulcer forms in the middle of the lesion.



**Fig. 2.** **a** Edema and redness in the eyelid improved, and areas of healing were seen in the middle of the lesion and on the edge of the intact skin (seventh day). **b** Healing of the lesion is seen on the 16th day.

Then, a scabbed scar tissue appears, the center of which turns black. The most important laboratory examination method for diagnosis is wound culture, but bacterial culture positivity is not a definitive diagnostic indication. Culture results may be negative in patients with a clinical diagnosis of anthrax, and a 6% bacterial culture positivity was found after systemic penicillin treatment in 1 study [7]. It has been suggested that bacterial culture results may turn negative 3–4 h after the use of systemic antibiotics. For differential diagnosis, furuncles, carbuncles, erysipelas, necrotizing cellulitis, and other necrotizing infective ulcers should be evaluated, and bacterial culture should be taken before starting antibiotic therapy [6, 8]. In our case, anthrax was detected in the wound culture of the lesion, and clinical findings confirmed the diagnosis of periocular anthrax. There was no growth in the wound cultures we took after antibiotic treatment was started.

There are different rates of lower and upper lid involvement in reported cases of palpebral anthrax. Farpour [9] reported upper eyelid involvement in 26 of 47 palpebral cases (55.3%). Tekin et al. [6] reported 15 upper eyelid involvement in a series of 21 cases (71.4%). Yorston and Foster [10] also reported 6 upper eyelid cases in 11 cases (54.5%). Although our case is limited to the upper eyelid, it is important to keep in mind that palpebral anthrax may involve the upper and lower eyelids.

It has been reported that the mortality rate is <1%, when anthrax is treated with appropriate drugs, especially with the efficacy of antibiotics. However, mortality rates up to 10–20% have been reported in untreated cases causing septicemia. According to in vitro antibiotic sensitivity tests, it has been reported that anthrax is sensitive to many antibiotics, and the most commonly used group drug is penicillin. Penicillin, amoxicillin, ampicillin, ciprofloxacin, and cefazolin can be used alone or in combination for systemic therapy. Topical antibiotics can be used in addition to systemic treatment in skin lesions [3, 6, 11]. In this case, amoxicillin from the penicillin family and ciprofloxacin were used as systemic treatment, and chloramphenicol was used topically.

Anthrax outbreaks can sometimes be seen in endemic areas. Livestock and agricultural workers or people who come into contact with raw meat should pay attention to hygiene and avoid touching the face and eyelid. In eyelid skin infections with clinical findings specific to anthrax, direct or indirect contact of infected animals should be questioned, and treatment should be applied immediately.

## Acknowledgment

There is no institution or person who contributed to the manuscript to be mentioned.

## Statement of Ethics

The authors have no ethical conflicts to explain. The patient was informed for publication, including images, and written informed consent was obtained. This study complied with the ethical criteria for medical research involving human subjects as specified in the Declaration of Helsinki. This study protocol was reviewed, and the need for approval was waived by the Tekirdağ Namık Kemal University Local Ethics Committee. This decision was made because it was a case report that was not a systematically designed study.

## Conflict of Interest Statement

The authors declare no conflicts of interest.

## Funding Sources

This research did not receive any funding.

## Author Contributions

Dr. Celik and Dr. Gonen examined the patient and wrote and reviewed the manuscript. Both of the authors read, edited, and approved publishing this case report.

## Data Availability Statement

All data generated and analyzed in this case report are included in the manuscript. Additional questions regarding data can be directed to the corresponding author.

## References

- 1 Procop G, Church D, Hall G, Janda W, Koneman E, Schreckenberger P, et al. Aerobic and facultative gram positive bacilli. *Koneman's color atlas and textbook of diagnostic microbiology*. 7th ed. Philadelphia: Wolters Kluwer; 2017. p. 844–959.
- 2 Winkler S, Enzenauer RW, Karesh JW, Pasteur N, Eisnor DL, Painter RB, et al. Case report of an anthrax presentation relevant to special operations medicine. *J Spec Oper Med*. 2016 Jun–Aug;16(2):9–12.
- 3 Gelaw Y, Asaminew T. Periocular cutaneous anthrax in Jimma Zone, Southwest Ethiopia: a case series. *BMC Res Notes*. 2013 Aug 7;6:313.
- 4 Akbayram S, Doğan M, Akgün C, Peker E, Bektaş MS, Kaya A, et al. Clinical findings in children with cutaneous anthrax in eastern Turkey. *Pediatr Dermatol*. 2010 Nov–Dec;27(6):600–6.
- 5 Çaça I, Cakmak SS, Unlü K, Sakalar YB, Kadiroglu AK. Cutaneous anthrax on eyelids. *Jpn J Ophthalmol*. 2004 May–Jun;48(3):268–71.
- 6 Tekin R, Ari S, Dal T, Kaya S, Kortak MZ, Dursun B, et al. Evaluation of cutaneous palpebral anthrax. *Cutan Ocul Toxicol*. 2013 Oct;32(4):294–8.
- 7 Demirdag K, Ozden M, Saral Y, Kalkan A, Kilic SS, Ozdarendeli A. Cutaneous anthrax in adults: a review of 25 cases in the eastern Anatolian region of Turkey. *Infection*. 2003 Oct 1;31(5):327–30.

- 8 Eshraghi B, Zarrin Y, Fazel M. Palpebral anthrax, a rare though important condition in villagers: a case report and literature review. [Int J Infect Dis](#). 2020 Oct;99:260–2.
- 9 Farpour H. Lésions charbonneuses de la paupière. [Bull Soc Fr Ophtalmol](#). 1973;385:385–94.
- 10 Yorston D, Foster A. Cutaneous anthrax leading to corneal scarring from cicatricial ectropion. [Br J Ophthalmol](#). 1989 Oct 1;73(10):809–11.
- 11 Esmer O, Karadag R, Bilgili SG, Gultepe B, Bayramlar H, Karadag AS. Three eyelid localized cutaneous anthrax cases. [Cutan Ocul Toxicol](#). 2014 Dec;33(4):345–7.

Copyright of Case Reports in Ophthalmology is the property of Karger AG and its content may not be copied or emailed to multiple sites or posted to a listserv without the copyright holder's express written permission. However, users may print, download, or email articles for individual use.