

Pacemaker Leads Extraction after Pocket Infection with Abdominal Vena Cava and Common Iliac Vein Thrombosis

Sir,

A 65-year male with a history of hypertension, type II diabetes mellitus (DM), and coronary artery disease attended the Outpatients' Clinic with orthopnea. Serial electrocardiograms showed sinus rhythm, and prolonged QRS duration (160–200 ms) with left bundle branch block. Non-sustained ventricular tachycardia attacks were determined at the rhythm Holter recording at another hospital. The patient's condition was classified as New York Heart Association (NYHA) class III. The left ventricular ejection fraction (LVEF) was 20% with M-mode measurement. Cardiac resynchronisation therapy with defibrillator (CRT-D) implantation was planned after levosimendan infusion and medical treatment for heart failure.

Two years after CRT-D implantation, the patient presented to Outpatient Clinic with fever and swelling in the pacemaker pocket area. Inflammatory markers were raised. The collection in the pacemaker pocket area was emptied and the samples were sent to the microbiology laboratory. Ceftriaxone 2g OD and metronidazole 500mg x3 were added after consultation by the Infectious Diseases Department. Vegetations and thrombi were not observed on transthoracic echocardiography (TTE) and transesophageal echocardiography (TEE).

In pacemaker controls, the patient's left ventricular lead was not working properly. A decision was made about removing the pacemaker after counselling. The patient's pacemaker and atrial lead were removed via percutaneous technique. The right ventricular and coronary sinus leads could not be removed due to adhesions. The patient's blood and urine culture showed no growth. In samples taken from the infected pocket area, *enterobacter cloacae* complex was grown. Antibiotic treatment of the patient was changed to ertapenem plus gentamicin.

After 14 days of treatment, the patient's acute phase reactants regressed. Leukocyte scintigraphy was planned as no vegetations were observed on TEE and TTE. The infectious focus was not detected. The patient, without fever and regressed acute phase reactants, was discharged with instructions for follow-up.

Two months later, the patient presented to Emergency Department with complaints of abdominal pain, nausea, and vomiting. No pathology was observed on abdominal ultrasonography, performed in the Emergency Department. In the abdominal computed tomography, a hyperdense image compatible with

the pacemaker lead, starting from the inferior vena cava to the right iliac vein was observed. For this, the patient underwent diagnostic laparoscopy by the general surgery team, and no pathology was observed. There was an extensive thrombus around lead in the lower extremity Doppler ultrasonography. The lead, which fell into the inferior vena cava, could not be caught with snare due to dense thrombus (Figure 1). The patient was taken to the Angiography Laboratory again after giving 50mg of tissue plasminogen activator (t-PA) for 24 hours. After t-PA infusion, we could easily extract the right ventricular lead and the coronary sinus lead with 30mm snare, coronary sinus ablation catheter, and right Amplatz 1 guiding catheter (Figure 2).

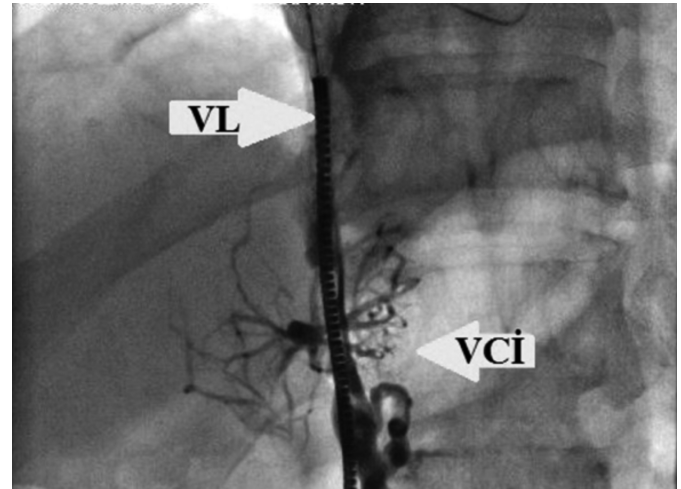


Figure 1: Thrombosed inferior vena cava. VL: Ventricular lead; IVCI: Inferior vena cava.

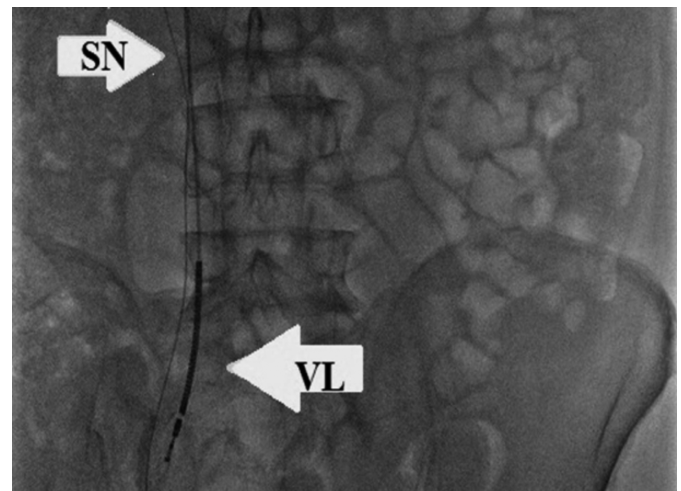


Figure 2: Extraction of the ventricular lead with snare. SN: Snare, VL: Ventricular lead.

Warfarin was started due to extensive thrombosis.^{1,2} Meropenem plus vancomycin was initiated, after *pseudomonas* growth in leads sent to the microbiology laboratory. The patient, whose complaints regressed after the treatment, was discharged with instructions for follow-up.

In conclusion, this case describes the removal of a thrombosed right ventricular and coronary sinus leads of the CRT-D device

after a pocket infection. In pacemaker endocarditis, the pacemaker system should be removed completely and long-term intravenous antibiotic treatment should be given.

PATIENTS' CONSENT:

This case was granted waiver of informed consent by the Institutional Review Board.

CONFLICT OF INTEREST:

The authors declared no conflict of interest.

AUTHORS' CONTRIBUTION:

CA: Wrote the manuscript.

SA, DOG: Performed the literature review.

MME, SG: Collected the pictures and gathered important clinical information.

REFERENCES

1. Chua JD, Wilkoff BL, Lee I, Juratlil N, Longworth DL, Gordon SM. Diagnosis and management of infections involving implantable electrophysiologic cardiac devices. *Ann Intern Med* 2000; **133(8)**:604-8. doi: 10.7326/0003-4819-133-8-

200010170-00011.

2. Cacoub P, Leprince P, Nataf P, Hausfater P, Dorent R, Wechsler B, et al. Pacemaker infective endocarditis. *Am J Cardiol* 1998; **82(4)**:480-4. doi: 10.1016/s0002-9149(98)00365-8.

Cihan Aydin¹, Seref Alpsoy¹, Demet Ozkaraman Gur¹,
Muhammed Mucip Efe¹ and Selami Gurkan²

¹Department of Cardiology, Faculty of Medicine, Namık Kemal University, Tekirdag, Turkey

²Department of Cardiovascular Surgery, Faculty of Medicine, Namik Kemal University, Tekirdag, Turkey

Correspondence to: Dr. Cihan Aydin, Department of Cardiology, Faculty of Medicine, Namık Kemal University, Tekirdag, Turkey

E-mail: drcihanaydin@hotmail.com

Received: September 03, 2020; Revised: November 02, 2021; Accepted: November 21, 2021

DOI: <https://doi.org/10.29271/jcpsp.2022.04.550>

