

Acute Kidney Injury in a Case of Purpura Fulminans Developing Secondary to Antithrombin 3 Deficiency

Gülsüm Özkan¹, Gaye Kübra Emeksiz², Reşit Volkan Atar², Samet Sedef²,
Pınar Sonat Kara², Meltem Öznur³ and Burhan Turgut⁴

¹Department of Nephrology, Namık Kemal University, School of Medicine, Tekirdağ, Turkey

²Department of Internal Medicine, Namık Kemal University, School of Medicine, Tekirdağ, Turkey

³Department of Pathology, Namık Kemal University, School of Medicine, Tekirdağ, Turkey

⁴Department of Hematology, Namık Kemal University, School of Medicine, Tekirdağ, Turkey

Purpura fulminans associated with antithrombin 3 (AT 3) deficiency is very rare in adults and neonates. It can be categorized into three principal forms - neonatal, idiopathic and acute infectious. Purpura fulminans has been reported to cause cardiac, pulmonary and renal damage in rare cases. We describe an adult case of purpura fulminans developing in association with AT 3 deficiency without infection following a surgical procedure, and acute kidney injury (AKI) developing secondary to rhabdomyolysis and disseminated intravascular coagulation (DIC). To the best of our knowledge there have been no previous cases of purpura fulminans and AKI developing in association with acquired AT 3 deficiency without infection after surgery. (*J Nippon Med Sch* 2018; 85: 56–59)

Key words: purpura fulminans, acute kidney injury, antithrombin 3 deficiency

Introduction

Purpura fulminans is characterized by intravascular thrombosis, collapse in cutaneous vessels and rapidly progressing hemorrhagic infarction and disseminated intravascular coagulation (DIC)¹. Purpura fulminans can be categorized into three principal forms - neonatal, idiopathic and acute infectious². All three forms present and are treated differently. Protein C, protein S and AT 3 deficiency are implicated in the etiology of purpura fulminans, resulting in DIC and purpura progressing to gangrenous lesions³. Idiopathic purpura fulminans frequently emerges after a latent period following a febrile infection, and DIC and multiorgan dysfunction subsequently develop⁴. The acute infectious form generally develops following meningococcal or Varicella zoster virus infection⁵.

We describe an adult case of purpura fulminans developing in association with AT 3 deficiency without infection following a surgical procedure, acute kidney injury (AKI) developing secondary to rhabdomyolysis and DIC, and the successful treatment thereof. The rarity of this case makes it particularly interesting.

Case Presentation

A 32-year-old male patient, undergoing surgery in an external center due to acute appendicitis, presented to our emergency department on the 7th day postoperatively due to lethargy, hematuria, decreased urine output and eruptions on his lower extremities. On physical examination, he was confused, and orientation and cooperation were weak. His blood pressure was 90/60 mm/Hg, heart rate was 120 beats per minute, body temperature was 37.2°C, and partial pressure of oxygen was 70%. Diffuse purpura were present on both lower extremities, pulses were palpable bilaterally and a right lower quadrant abdominal scar secondary to an operation was visible. The patient's general condition was poor, and his oxygenation was low. He was intubated and transferred to the intensive care unit. The patient was extubated on the 2nd day after admission. Biochemistry, complete blood count and coagulation values are shown in **Table 1**. No bacterial growth was determined in his blood or urine cultures. At follow-up, his urine output was 160 mL/day and his creatinine was 6.4 mg/dL, and hemodialysis was

Correspondence to Dr. Gülsüm Özkan, Department of Nephrology, Namık Kemal University, School of Medicine, 59000 Tekirdağ, Turkey

E-mail: gulsumozkan78@hotmail.com

Journal Website (<http://www2.nms.ac.jp/jnms/>)

Table 1 Biochemical parameters of the patient

	At the time of admission	At the time of extubation	5th day of intravenous heparinization	At the time of discharge
BUN (mg/dL)	125	124	97	32
Cr (mg/dL)	5.11	6.32	6.13	1.08
Na (mmol/L)	133	135	133	140
K (mmol/L)	5.41	4.86	4.68	5.16
Ca (mg/dL)	9.6	8.5	8.5	9.8
P (mg/dL)	8.7	7.3	6.3	3.7
TP (g/dL)	6.1	5.7	6.1	8.5
Alb (g/dL)	2.9	2.6	2.7	3.8
UA (mg/dL)	6.9	8	5.5	5.4
CK (U/L)	175			
Myg (ng/mL)	269	65		
Hb (g/dL)	11.1	7.1	8.5	12.8
WBC (U/L)	12.700	13.600	8.600	6.700
PLT (U/L)	166.000	260.000	501.000	343.000
Urinalysis density	1,009			1,020
Protein (mg/dL)	-			-
Erythrocytes	-			-
CRP (mg/dL)	85.5	49.8		
PT	14.8	14.4	16.1	23.9
aPTT	26.7	57.2	35.2	30.06
INR	1.15	1.06	1.22	1.67
Protein C (%)	113			
Protein S (%)	76			
Antithrombin 3 (%)	23		21	26

BUN: Blood urea nitrogen; Cr: Creatinine; TP: Total protein; Alb: Albumin; Ca: Calcium; P: Phosphorus; CK: Creatine kinase; Na: Sodium; K: Potassium; UA: Uric acid; WBC: White blood cells; Hb: Hemoglobin; PLT: Platelets; Myg: Myoglobin; CRP: C-reactive protein; PT: Prothrombin time; aPTT: Partial Thromboplastin Time; INR: International Normalized Ratio

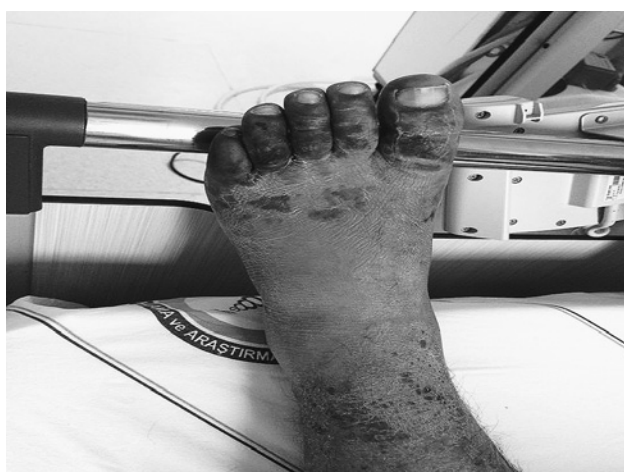

Fig. 1 Erythematous lesions in the healing phase in both lower extremities and gangrenous lesions in the toes

therefore scheduled. A myoglobin level of 269 ng/mL (25–85 ng/mL) was determined at tests performed to identify the etiology of his acute kidney injury. Urinary

ultrasonography was normal. Rhabdomyolysis was suspected. At follow-up, the purpura spread to his toes and a gangrenous appearance developed. The dermatology and cardiovascular surgery departments were consulted (Fig. 1). Arterial thrombosis was not suspected. ANA and anti-dsDNA were negative, Protein C was 113% (70–130%), and AT 3 activity was 23% (80–120) at tests performed for the purpuric lesions with a preliminary diagnosis of vasculitis and purpura fulminans. A punch biopsy was taken from the purpuric lesions. The pathology result was compatible with purpura fulminans (Fig. 2). AT 3 deficiency-related purpura fulminans was diagnosed. The patient was started on intravenous heparinization. He continued to receive hemodialysis therapy, and his urine output began to increase on day 5 of intravenous heparinization. His urea and creatine values then returned to normal, and the patient was discharged with enoxaparin and warfarin. Improvement in the cutaneous lesions was observed at nephrology and hematology clinic follow-up. The patient's urea and creatinine values

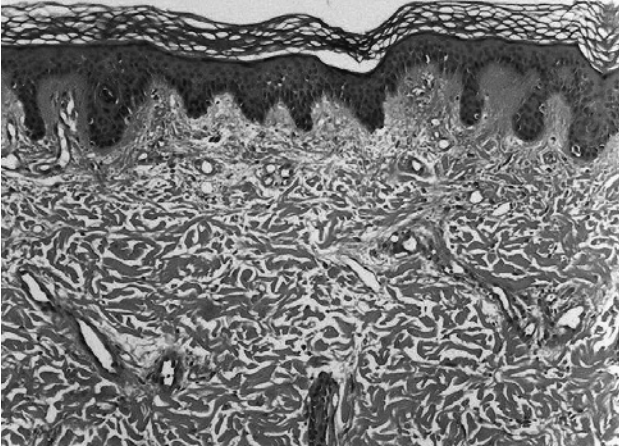


Fig. 2 Regular structure of the epidermis, and erythrocyte extravasation with the presence of telangiectatic vessels in the dermis

are still within normal limits, and treatment is continuing with warfarin.

Discussion

Purpura fulminans is a disease that is frequently seen in newborns but rarely in adults, in whose etiology gram negative bacteria are frequently involved, and that presents with cutaneous vascular collapse, edema, necrosis and gangrene¹⁻³. In our patient, purpura fulminans was diagnosed after a punch biopsy from eruptions emerging following an appendectomy. AT 3 deficiency was determined from the known etiological factors.

AT 3 is a natural anticoagulant. AT 3 deficiency can be congenital or acquired. Congenital forms occur as a result of antithrombin gene mutations, while acquired forms can also accompany conditions such as liver disease or warfarin therapy in which AT 3 production decreases, nephrotic syndrome in which loss worsens, or acute thrombosis or DIC in which consumption increases⁶⁻⁸. AT 3 deficiency may rarely be observed following major surgery⁹. Although the low AT3 level after surgery cannot be fully explained, it may perhaps be due to consumption associated with the process arising from tissue trauma in the surgical procedure¹⁰. In our case, we think that AT 3 deficiency developed secondary to surgery and DIC developed following surgery. The balance between the procoagulant and anticoagulant systems is compromised in patients with purpura fulminans. Impairment of this balance is thought to be associated with increased release and consumption of various cytokines in conditions such as sepsis and tissue injury. In individuals with AT3 deficiency, these conditions result in an even greater deficiency and eventually in the formation

of multiple thrombi in various tissues. Diffuse thrombi in cutaneous vessels lead to the development of purpura fulminans¹¹.

Compatibly with the presentation, gangrenous lesions were present in the lower extremities, particularly the toes. Cardiac, hepatic and renal damage have rarely been reported in purpura fulminans in previous studies⁵. We considered that the development of acute kidney injury together with eruptions in our case was secondary to purpura fulminans-associated DIC and rhabdomyolysis. Previous cases have been reported of acute kidney injury developing following purpura fulminans and/or rhabdomyolysis secondary to various infections¹²⁻¹⁴. In the adult age group, purpura fulminans associated with protein C and S, and antithrombin 3 deficiency generally emerges with the development of antibodies to these coagulation proteins after an infection. However, we determined no infectious agent in our patient. Only an appendectomy before presentation to our hospital was present in his history. This distinguishes this case from others in the literature. To the best of our knowledge, this is the first case of acute kidney injury and purpura fulminans developing in association with AT 3 deficiency after surgery.

The recommended treatment of purpura fulminans in the guidelines involves treatment of sepsis with appropriate antibiotics, adjustment of coagulation with requisite replacements, debridement of gangrenous lesions in the extremities under suitable conditions, and even amputation¹⁵. We determined no infection in our patient. No further hemodialysis was required on the 5th day of heparinization. Our patient is still being followed-up and treated with no cutaneous lesions or organ dysfunction following warfarin therapy.

In conclusion, antithrombin 3 deficiency may constitute a rare cause of purpura fulminans, purpura fulminans can be triggered following a surgical procedure in adults with AT 3 deficiency, and rhabdomyolysis should not be overlooked in the development of acute kidney injury in such cases.

Conflict of Interest: We report no conflicts of interest.

References

1. Kondaveetti S, Hibberd ML, Booy R, Nadel S, Levin M: Effect of the Factor V Leiden mutation on the severity of meningococcal disease. *Pediatr Infect Dis J* 1999; 18: 893-896.
2. Andreasen TJ, Green SD, Childers BJ: Massive Infectious soft-tissue injury: diagnosis and management of necrotizing fasciitis and purpura fulminans. *Plast Reconstr Surg* 2001; 107: 1025-1035.

3. Sen K, Roy A: Management of neonatal purpura fulminans with severe Protein C deficiency. *Indian Pediatr* 2006; 43: 542–545.
4. Brown DL, Greenhalgh DG, Warden GD: Purpura fulminans: a disease best managed in a burn center. *J Burn Care Rehabil* 1998; 19: 119–123.
5. Madden RM, Gill JC, Marlar RA: Protein C and protein S levels in two patients with acquired purpura fulminans. *Br J Haematol* 1990; 75: 112–117.
6. Raya-Sánchez JM, González-Reimers E, Rodríguez-Martín JM, Santolaria-Fernández F, Molina-Pérez M, Rodríguez-Moreno F, Martínez-Riera A: Coagulation inhibitors in alcoholic liver cirrhosis. *Alcohol* 1998; 15: 19.
7. Mammen EF: Antithrombin: its physiological importance and role in DIC. *Semin Thromb Hemost* 1998; 24: 19.
8. Kauffmann RH, Veltkamp JJ, Van Tilburg NH, Van Es LA: Acquired antithrombin III deficiency and thrombosis in the nephrotic syndrome. *Am J Med* 1978; 65: 607.
9. Lechner K, Kyrle PA: Antithrombin III concentrates—are they clinically useful? *Thromb Haemost* 1995; 73: 340.
10. Paparella D, Cappabianca G, Scrascia G, Fiore G, Paramythiotis A, Di Bari N, Liuzzi MP, Ibrahim MF, Fiore T, de Luca Tupputi Schinosa L: Antithrombin after cardiac surgery: implications on short and mid-term outcome. *J Thromb Thrombolysis* 2009; 27: 105–114.
11. Murad AA, Jeffers M, Tobin AM, Connolly M: Purpura fulminans in a patient with mixed connective tissue disease. *BMJ Case Rep* 2013; 30: 2013.
12. Chaudhary SC, Kumar V, Gupta A: Purpura fulminans: a rare presentation of a common disease. *Trop Doct* 2010; 40: 238–239.
13. Marín GR, Baspineiro B, Miranda MR, Cabello M: Purpura fulminans, cerebral infarcts and multiorgan dysfunction due to hantavirus infection. Review and case report. *Arch Argent Pediatr* 2009; 107: 60–65.
14. Fortenberry JD: Pediatric critical care management of septic shock prior to acute kidney injury and renal replacement therapy. *Semin Nephrol* 2008; 28: 447–456.
15. Levin M, Eley BS, Louis J, Cohen H, Young L, Heyderman RS: Postinfectious purpura fulminans caused by an autoantibody directed against protein S. *J Pediatr* 1995; 12: 355–363.

(Received, August 2, 2017)

(Accepted, October 2, 2017)