



Comparison of Drainage, Delayed Pits Excision, and Closure With Excision and Secondary Healing in Pilonidal Sinus Abscess Cases

Selim Sözen¹, Mehmet Aziret², İlhan Bali¹, Ali Cihat Yıldırım³

¹Namik Kemal University of Medical School, Department of General Surgery, Tekirdağ, Turkey

²Sakarya University of Medical School, Department of General Surgery, Sakarya Turkey

³Kars State Hospital, Department of General Surgery, Kars, Turkey

A pilonidal abscess is an emergency situation which requires immediate drainage and is usually seen in young men. We aimed to compare incision and draining (I&D) of acute pilonidal abscess (PSA) and healing by secondary intention with I&D and subsequent delayed pits excision and closure (PE/PC). A total of 62 patients admitted with PSA were randomized to undergo either I&D and healing by secondary intention (group 1, n = 33) or I&D and PE/PC (group 2, n = 29). Demographic characteristics of the patients, abscess depth and location, duration and healing times of the symptoms, time required to return to work, and ratio of chronic pilonidal sinus (PNS) development were recorded, and the two methods were compared. No statistically significant differences were found between the groups in relation to sex, age, and preoperative findings, including discharge, infection, pain, and length and depth of abscess. There was no difference in length of hospital stay between the groups, and no statistically significant difference was found between the groups in terms of complication rate ($P = 0.298$). A statistically significant difference ($P = 0.033$) was, however, found between the two groups in the recurrence rate of a pilonidal abscess (9.09% in group 1 versus 3.44% in group 2). A statistically significant difference was also observed between the groups in terms of development of chronic PNS ($P = 0.020$). According to the results of our study, I&D and PE/PC should be the primary procedure used, as opposed to skin incision, curettage, and secondary healing for the treatment of PSA.

Key words: Pilonidal abscess – Drainage – Excision – Incision

Corresponding author: Mehmet Aziret, MD, Adnan Menderes Street Sağlık Sok. No: 195 Adapazarı, Turkey.
Tel.: 90 5063057317; Fax: 90 (264) 275 91 92; E-mail: mhmtaziret@gmail.com

A pilonidal sinus (PNS) is a common condition that affects young to middle-aged adult men. The pathogenesis remains uncertain, with arguments suggesting both congenital and acquired bases for the etiology of this condition.¹ PNS disease is caused by the penetration of hairs into the skin of the gluteal cleft, which, due to foreign body reaction, leads to cyst and sinus formation followed by secondary infections and abscesses.²

A pilonidal abscess is one of the most common complications associated with pilonidal disease.^{3,4} Pilonidal abscesses may lead to large tissue damage and sepsis unless treated. Pilonidal sinus, which is associated with abscess exacerbations, may spread to the anal canal or perianal region.^{5,6} Despite the variety of surgical techniques proposed for the treatment of PSA, the “best method” to use is still a matter of debate.⁷ Conventional treatment of a pilonidal abscess is incision and simple drainage whereby large tissue damage is prevented and the patient is relieved of pain. However, chronic PNS develops in 16% to 92.5% of patients following a simple drainage. In these cases, surgical treatment is required.^{8–10} The ideal approach for treating pilonidal disease should be simple, inflict minimal pain, have the best chance for cure and least local recurrence rate, avoid admission to the hospital, not require general anesthesia, require minimal wound care, pose minimal inconvenience, and require the least amount of time off work for the patient.^{1,11} This study was performed to compare incision and draining (I&D) of PSA and healing by secondary intention with I&D and delayed pits excision and closure (PE/PC).

Materials and Methods

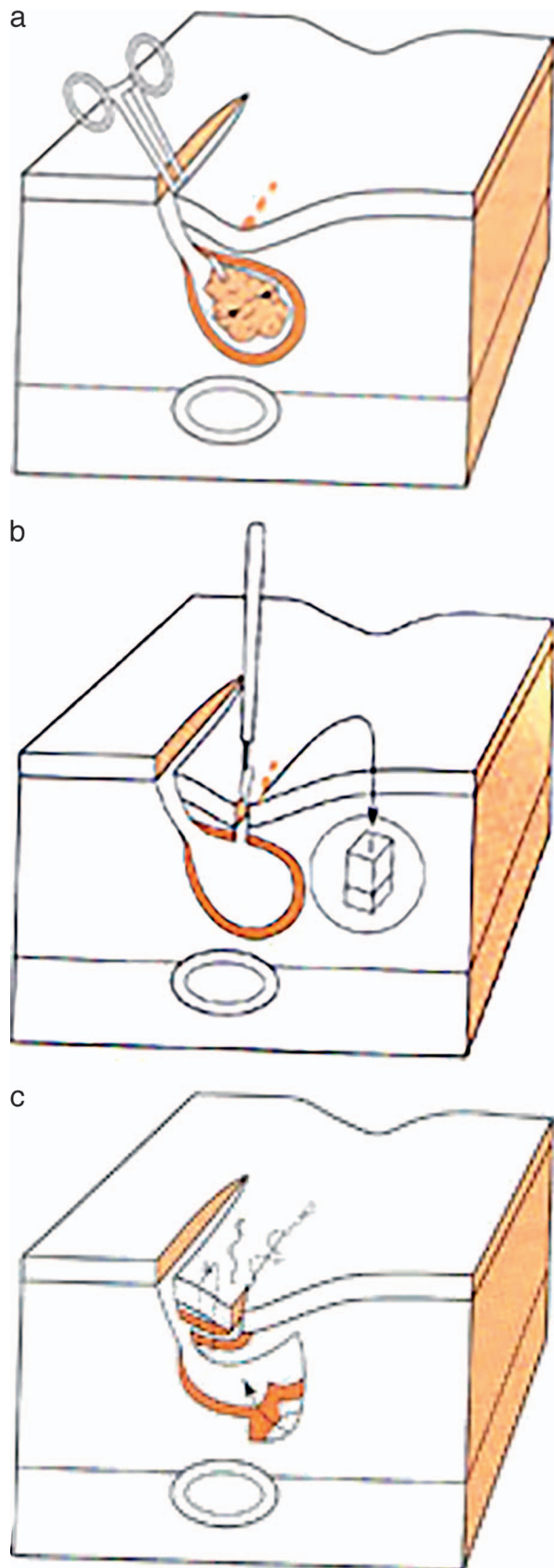
Patients

Patients who were treated for PSA in our clinic between January 2009 and January 2013 were analyzed retrospectively. A total of 62 patients who had fulfilled the criteria completed the study. Data were obtained from the records in the archive of the hospital (operation notes, epicrisis, and polyclinic dressing records). In 33 patients, excision and curettage were performed on the abscess and then left alone to undergo secondary healing (group 1). In 29 patients, the pits of the epithelized PNS were excised with a small incision 5 days after the abscess drainage (group 2). Prior to participation in the study, written informed consent was received from the patients. Inclusion criteria for participation in the study included the presence of a PSA and

subsequent surgery in adult patients over the age of 16, an international normalizing ratio (INR) less than 1.5 IU, a prothrombin time of less than 15 seconds, a normal or near normal partial thromboplastin time, a platelet count greater than 50,000/mm³ to limit the risk of bleeding, and the absence of any infection at the time of surgery. The exclusion criteria included those patients who were unwilling to give their written informed consent and those who were unable to be reached, patients who were younger than 16 years old, patients presenting with conditions mimicking PNS, such as pilonidal cysts, and patients with diabetes mellitus, renal failure, or immunosuppression.

Surgical technique

Both methods were applied under local anesthesia. The operative field was shaved and cleaned with povidon-iodine. An adequate amount of lidocaine HCl 40 mg/2 mL + epinephrine 0.025 mg/2 mL infiltration was administered to the fluctuating field and surrounding areas when the patient was in prone position. In the patients who received a skin incision and curettage, a skin incision averaging 3 × 2 cm was performed in the fluctuating field. After evacuating the abscess, the whole cavity was curetted and washed with hydrogen peroxide, and then the remaining material was removed. Dressing was done with saline solution twice daily during the first 3 days and daily thereafter. Patients in group 1 were left to heal by secondary intention. In group 2, the cavity was left open for drainage after being washed with hydrogen peroxide first and saline thereafter, following simple drainage (simple drainage was applied from a parallel vertical incision of 2 cm in lateral if the abscess cavity was in midline and with a vertical incision directly over the abscess cavity if it was outside of the midline). After an average of 5 days, midline pilonidal pits were excised with small diamond-shaped incisions. Midline wounds were closed with a subcuticular suture, and lateral wounds were permitted to heal by granulation (Figs. 1 and 2).¹¹ Microbiologic samples were obtained for culture, and empirical antibiotic treatment was started in both groups. Daily wound dressings were recommended for the first week, followed by three dressings the second week and then two dressings a week thereafter. Patients were instructed to adhere to hygiene measures by taking showers and using a towel to rub away loose hairs and to undertake hair depilation to prevent small



hairs from making their way into the cavity or overlooked small pits.

The patients were followed up for a mean of 24 months (12–36 months). Demographic characteristics of the patients, abscess depth and location, duration and healing times of the symptoms, time required to return to work, and ratio of chronic pilonidal sinus development were recorded, and the two methods were compared.

Statistical analysis

Statistical analyses were performed using SPSS/PC version 13 software (Prentice-Hall, Chicago, Illinois). The Student *t* test was used to compare the mean values between the two groups. The χ^2 test with Yate's correction was used for comparison between categorical qualitative values, and Fisher's exact test was used for comparing recurrence between the two study groups. A *P* level of <0.05 was accepted to be statistically significant.

Results

A total of 62 patients who were treated for PSA in our clinic were included in the study. No patients had a previous pilonidal abscess surgery. Associated cellulitis was present in the majority of patients in each group (90.9% in group 1 versus 93.1% in group 2), and abscesses were located in the midline in nearly half of the patients in either group (57.5% versus 51.7%, respectively). The length and depth of abscess in primary and secondary groups are shown in Table 1. There were no statistically significant differences between the groups in relation to sex, age, and preoperative findings, including discharge, infection, pain, and the length and depth of the abscess. During follow-up, 3.03% of patients (*n* = 1) in group 1 and 3.44% in group 2 (*n* = 1) developed an infection (wound infection). Table 2 shows that the two groups did not differ significantly from each other regarding hospital stay and time required to return to work or resume normal physical activity. Complications were observed in 6 of the 62 patients

←

Fig. 1 Lateral off-midline drainage, excision of midline pits. (a) Sinuses were opened through an incision 2 cm lateral and parallel to the natal cleft.¹¹ (b) Midline pilonidal pits were excised by small diamond-shaped incisions.¹¹ (c) Midline wounds were closed with a subcuticular suture and lateral wounds permitted to heal by granulation.¹¹

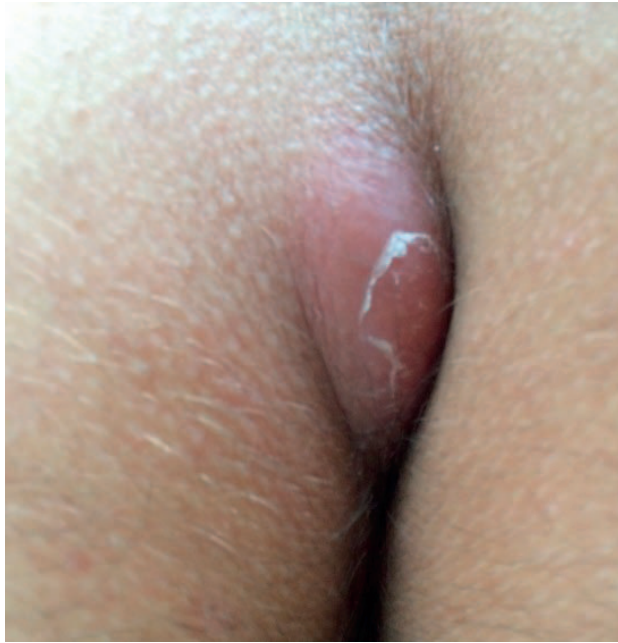

Fig. 2 A pilonidal sinus abscess.

(9.6%): 3 patients (9.09%) in group 1 and 3 (10.3%) in group 2. There was no statistically significant difference between the groups in terms of complication rate ($P = 0.298$). Recurrence was detected in four patients (6.45%). No statistically significant differences were found between the groups in relation to recurrence and development of chronic PNS. The difference in the recurrence rate of a pilonidal abscess, however, was statistically significant ($P = 0.033$) between the two groups (9.09% in group 1 versus 3.44% in group 2). Lastly, a statistically significant difference was observed

Table 1 Patient characteristics and clinical presentation in both groups

Characteristic features	Group 1	Group 2	<i>P</i>
Number of patients	33	29	0.455
Male (n, %)	31 (93.9)	27 (93.1)	0.930
Female (n, %)	2 (6.06)	2 (6.8)	
Mean age (years)	24.6 ± 2.3	23.8 ± 6.8	0.185
Length of abscess (cm)	2.5 ± 1.2	2.6 ± 1.3	0.21
Depth of abscess (cm)	2.7 ± 1.5	2.5 ± 1.7	0.52
Location of the abscess			
Midline (n, %)	19 (57.5)	15 (51.7)	0.726
Off-midline (n, %)	12 (36.3)	12 (41.3)	
Both (n, %)	22 (60.6)	2 (6.8)	
Pre-operation findings			
Pain (n, %)	31 (93.9)	28 (96.5)	0.461
Cellulitis (n, %)	30 (90.9)	27 (93.1)	
Swelling (n, %)	28 (84.8)	28 (96.5)	
Discharge (n, %)	25 (75.7)	26 (91.7)	

Table 2 Postoperative course and complications in both groups

Postoperative course and complications	Group 1	Group 2	<i>P</i>
Hospital stay (hours)	1.1 ± 0.7	1.4 ± 0.3	0.46
Mean healing time (days)	33.7 ± 9.3	32.5 ± 8.8	0.52
Return to normal activity (days)	8.8 ± 2.1	9.8 ± 2.3	0.92
Complications			
Wound infection (n, %)	1 (3.03)	1 (3.44)	0.29
Bleeding (n, %)	2 (6.06)	2 (6.89)	
Recurrence of acute abscess (n, %)	3 (9.09)	1 (3.44)	0.033
Development of chronic PNS (n, %)	6 (18.2)	1 (3.44)	0.020

Bold numbers indicate statistical significance.

between the groups in terms of development of chronic PNS ($P = 0.020$).

Discussion

A pilonidal abscess is one of the most common complications of pilonidal disease.^{3,4} However, there is not yet a consensus about the optimal treatment.¹² Some authors believe that the incision and drainage method is an effective procedure. However, this method would treat only the acute infection and lead to the necessity of reoperation for definite therapy.⁷ Bascom proposed that the main etiologic factor was hair follicles and not the hair. He also suggested that the early chronic PNS development rate could be reduced to 15% by excising the epithelized pilonidal sinus mouth with a small incision 5 days after a simple drainage.¹³ Using the Bascom operation technique, sinuses were opened through a 2-cm lateral incision, parallel to the natal cleft. Bacteriology swabs were taken, and sinus cavities were allowed to drain freely through the lateral incision. Excision of the midline pilonidal pits were performed with small diamond-shaped incisions, and a buttress of fat was constructed to support the healing of the midline wound. Midline wounds were closed with a subcuticular suture, and lateral wounds were permitted to heal by granulation. We observed that with this technique chronic PNS developed 3.44% of the time.

The rate of recurrence with drainage of PSA and primary wound closure ranged from 14% to 38%.⁷ McLaren reported that surgical intervention was required in 40% of the patients who received an incision and drainage.¹⁴ Whereas Matter *et al* reported 16% recurrence with incision and drainage

in PSA, they detected 12% recurrence with excision and packing.¹⁵

There is currently no consensus about the curettage of the abscess wall. In relevant studies, the cure rate has been reported to be 76%.¹⁶ In addition, the combination of drainage and curettage is known to provide faster regression in symptoms compared to simple drainage. In our study, the abscess pouch was curetted and cleaned mechanically. Millar and Lord reported a 97% success rate with excision and mechanic cleaning under local anesthesia in PSA and chronic PNS.¹⁷ Incision (lay open) techniques with or without marsupialization have low recurrence rates, averaging approximately 8% over the long term.¹⁸ Isbister and Prasad proposed that lay open could be applied successfully in both conditions by arguing that it was unnecessary to discriminate between PSA and chronic PNS treatment. They reported PSA in 311 of 323 cases and 12% PNS development with lay open technique.¹⁹

A single-step radical treatment of a pilonidal abscess was performed, using drainage, curettage, and marsupialization, in 43 patients in the study conducted by Licheri *et al.* They reported a failure rate (persistent sinus or recurrence) of 18.7% and complete healing within 4–10 weeks in 95.3%.²⁰ Chronic PNS development was found to be 18.2% in the secondary healing group in our study. Hosseini *et al* compared drainage, delayed excision and primary closure with excision and secondary healing in the management of 76 patients with a pilonidal abscess and reported a significantly higher 1-year recurrence rate with primary closure.⁷ Sakr *et al* compared, drainage, delayed excision, and delayed closure with incision, drainage, and secondary healing, and reported speedier healing times and fewer visits required for dressing when I&D and delayed excision/delayed closure (DE/DC) was performed for PSA. However, a significantly higher overall complication rate was seen compared with I&D and secondary healing.³ Chronic PNS developed in 11.29% of the cases during the 24-month period of follow-up in the patients who were fully recovered. Although duration of hospital stay was 1.1 ± 0.7 hours and healing time was 33.7 ± 9.3 days in incision, drainage, and excision, in cases of incision and delayed pits removal, the duration of hospital stay was 1.4 ± 0.3 hours and healing time was 32.5 ± 8.8 days, with no statistically significant difference being found between the procedures. Healing time was significantly shorter in the incision and drainage group. The rate of recurrence

was considerably lower in patients receiving this procedure compared with those who underwent secondary healing.

The first intervention is of primary importance in PSA treatment and those methods that pose a lower risk for chronic PNS development should be preferred.

Conclusion

PSA needs definitive treatment after drainage to prevent it from becoming a chronic disease. Incision, drainage, and combined definitive surgery have been shown to be a reliable method of treatment. According to the results of our study, I&D, delayed pits excision, and closure should be the primary procedure used, as opposed to skin incision and curettage, in the treatment of acute pilonidal abscess.

Acknowledgments

There is no conflict of interest. This study was not supported by any institution and company.

References

1. Majeski J, Stroud J. Sacrococcygeal pilonidal disease. *Int Surg* 2011;**96**(2):144–147
2. da Silva JH. Pilonidal cyst: cause and treatment. *Dis Colon Rectum* 2000;**43**(8):1146–1156
3. Sakr MF, Ramadan MA, Hamed HM, Kantoush HE. Secondary healing versus delayed excision and direct closure after incision and drainage of acute pilonidal abscess: a controlled randomized trial. *Arch Clin Exp Surg* 2012;**1**(1):8–13
4. Vahedian J, Nabavizadeh F, Nakhaee N, Vahedian M, Sadeghpour A. Comparison between drainage and curettage in the treatment of acute pilonidal abscess. *Saudi Med J* 2005; **26**(4):553–555
5. Accarpio G, Davini MD, Fazio A, Senussi OH, Yakubovich A. Pilonidal sinus with an anal canal fistula. Report of a case. *Dis Colon Rectum* 1988;**31**(12):965–967
6. Vallance S. Pilonidal fistulas mimicking fistulas-in-ano. *Br J Surg* 1982;**69**(3):161–162
7. Hosseini SV, Bananzadeh AM, Rivaz M, Sabet B, Mosallae M, Pourahmad S *et al.* The comparison between drainage, delayed excision and primary closure with excision and secondary healing in management of pilonidal abscess. *Int J Surg* 2006;**4**(4):228–231
8. Matter I, Kunin J, Schein M, Eldar S. Total excision versus non-resectional methods in the treatment of acute and chronic pilonidal disease. *Br J Surg* 1995;**82**(6):752–753

9. Surrell JA. Pilonidal disease. *Surg Clin North Am* 1994;**74**(6): 1309–1315
10. Goodall P. The aetiology and treatment of pilonidal sinus: a review of 163 patients. *Br J Surg* 1961;**49**:212–218
11. Hull TL, Wu J. Pilonidal disease. *Surg Clin North Am* 2002; **82**(6):1169–1185
12. Solla JA, Rothenberger DA. Chronic pilonidal disease. An assessment of 150 cases. *Dis Colon Rectum* 1990;**33**(9):758–761
13. Bascom J. Pilonidal disease: long-term results of follicle removal. *Dis Colon Rectum* 1983;**26**(12):800–807
14. McLaren CA. Partial closure and other techniques in pilonidal surgery: an assessment of 157 cases. *Br J Surg* 1984;**71**(7):561–562
15. Matter I, Kunin J, Schein M, Eldar S. Total excision versus non-resectional methods in the treatment of acute and chronic pilonidal disease. *Br J Surg* 1995;**82**(6):752–753
16. Jensen SL. Prognosis after simple incision and drainage for a first episode acute pilonidal abscess. *Br J Surg* 1988;**75**(1):60–61
17. Lord PH, Millar DM. Pilonidal sinus: a simple treatment. *Br J Surg* 1965;**52**:298–300
18. Rakinic J. Sacrococcygeal pilonidal sinus. In: Cameron JL, ed. *Current Surgical Therapy* St. Louis, MO: Mosby; 1998:302–306
19. Isbister WH, Prasad J. Pilonidal disease. *Aust N Z J Surg* 1995; **65**(8):561–563
20. Licheri S, Pisano G, Erdas E, Farci S, Pomata M, Daniele GM. Radical treatment of acute pilonidal abscess by marsupialization. *G Chir* 2004;**25**(11-12):414–416