

Radiosurgery effects and adverse effects in symptomatic eloquent brain-located Cavernomas

Tanju Berber^{1,*}, Suat Erol Celik², Ferdi Aksaray¹, Adnan Yoney³,
Kemal Harmanci⁴, Makbule Tambas¹, Binnur Dönmez Yılmaz¹,
Cakir Numanoglu¹, Ahmet Yolcu⁵, Hilal İrem Açıkan¹, Selvi Tabak Dinçer¹ and
Berna Akkuş Yıldırım¹

¹Department of Radiation Oncology and Radiosurgery, Okmeydani Training And Research Hospital, Istanbul, Turkey

²Department of Neurosurgery, Okmeydani Training And Research Hospital, Istanbul, Turkey

³Department of Internal Medicine, Karadeniz Technical University Faculty of Medicine, Trabzon, Turkey

⁴Department of Radiology, Okmeydani Training And Research Hospital, Istanbul, Turkey

⁵Department of Radiation Oncology, Namık Kemal University Medical Faculty of Medicine, Tekirdag, Turkey

*Corresponding author. Department of Radiation Oncology and Radiosurgery, Okmeydani Training And Research Hospital, Kaptan Pasa, SSK Okmeydani Hst.

No: 25, 34384 Sisli/Istanbul, Turkey. Tel: +905324111202; Email: tanjuerberber@hotmail.com

(Received 21 February 2022; revised 21 June 2022; editorial decision 11 August 2022)

ABSTRACT

In this study, the dose schedule efficacy, safety and late adverse effects of stereotactic radiosurgery (SRS) were evaluated for patients with symptomatic cavernomas who were not eligible for surgery and treated with SRS. Between January 2013 and December 2018, 53 patients with cavernomas were treated using SRS with the CyberKnife® system. Patients' diseases were deeply located or were in subcortical functional brain regions. In addition to bleeding, 23 (43.4%) patients had epilepsy, 12 (22.6%) had neurologic symptoms and 16 patients (30.2%) had severe headaches. The median volume was 741 (range, 421–1351) mm³, and the median dose was 15 (range, 14–16) Gy in one fraction. After treatment, six (50%) of 12 patients with neurologic deficits still had deficits. Rebleeding after treatment developed in only two (3.8%) patients. The drug was completely stopped in 14 (60.9%) out of 23 patients who received epilepsy treatment, and the dose of levetiracetam decreased from 2000 mg to 1000 mg in four (17.3%) of nine patients. Radiologically, complete response (CR) was observed in 13 (24.5%) patients, and partial responses (PR) were observed in 32 (60.2%) patients. Clinical response of CR was observed in 30 (56.6%) patients, PR was observed in 16 (30.2%), stable disease (SD) was observed in three (5.7%) and four (7.5%) patients progressed. In conclusion, SRS applied in the appropriate dose schedule may be an effective and reliable method in terms of symptom control and prevention of rebleeding, especially in patients with inoperable cavernomas.

Keywords: cavernoma; epilepsy; hemangioma; seizures; stereotactic radiosurgery (SRS); cerebral cavernous malformations (CCMs)

INTRODUCTION

Cavernomas are vascular structures made up of abnormally dilated blood vessels. The vascular structure in cavernomas is thick-walled and tends to leak and bleed due to the absence of elastin support, which creates a flexible structure between cells in normal blood vessels. Therefore, they are surrounded by hemosiderin residues and gliosis [1]. Cavernomas are found in 0.01–0.5% of the general population and constitute the majority (8–15%) of all brain and spinal cord vascular malformations. It is seen as familial in half of all cases. Familial cavernomas are autosomal dominant and can develop in many areas

of the brain [2, 3]. Nonfamilial tumors may develop sporadically and postoperatively due to trauma and vascular anomalies and present as de novo idiopathic tumors or after radiotherapy [4, 5].

Cavernomas are frequently undiagnosed anomalies. In many cases, cavernomas do not cause symptoms and may go unnoticed. Cavernomas, which can remain silent for years, are diagnosed incidentally [6, 7] or with headache, nausea, or treatment-resistant epileptic seizures (50%), which are often caused by hemorrhage or bleeding [8]. When untreated, the risk of rebleeding within the first 2.5 years after the first bleeding event is 2% per month and a cumulative 14% per year

[9]. The probability of occurrence of neurologic deficits and magnetic resonance imaging (MRI) findings due to rebleeding reaches up to 34% annually in patients who have two previous bleeding episodes [10, 11]. Treatment approaches with follow-up, microsurgery, or investigative stereotactic radiosurgery (SRS) are recommended in cavernomas. If a small amount of bleeding develops in a cavernoma with a superficial localization, it is usually followed up via MRI. Although microsurgery is the standard approach in cavernoma treatment, complications in this approach cannot be ruled out. SRS, which has less morbidity, would be more preferred, especially in deeply localized and inoperable cases, such as the skull base, brainstem and basal ganglion [12].

The approach to patients with symptomatic cavernomas in eloquent regions is still controversial [13]. If a patient has a hemorrhagic or symptomatic eloquent region, SRS may be the only option. Locations in the eloquent brain, even if there is a high probability of rebleeding of lesions that can leave sequelae, surgery can be avoided by taking complications into account [14]. A relatively new method, SRS, currently has no dose schedules that have been proven in prospective studies. There is not even a phase 2 study in the literature on the adverse effects that these doses can create in the brain over a long period. Much of what we know about cranial SRS comes from metastatic cranial tumor SRS applications [15]. Cranial SRS applications in metastatic disease are also a fairly new treatment method, and unfortunately, these patients have a very short survey. For this reason, late adverse effects of cranial SRS have not been well established because these patients die without observing BED₂ effects.

In this study, we aimed to determine the dosing schedule of SRS for patients with symptomatic cavernomas treated with SRS, and the effectiveness, safety, and long-term adverse effects were evaluated.

METHODS

Patient eligibility

Between January 2013 and December 2018, a total of 53 patients with symptomatic cavernomas who had bleeding at least once but not were considered for surgery and who were referred by the department of neurosurgery and decided to be given SRS by neurosurgery were retrospectively evaluated. The study was approved by Okmeydani Training and Research Hospital (No: 1166, Date: 05/03/2019). Patients were not required to give informed consent for the study because the analysis used anonymous clinical data that were obtained after each patient had agreed to treatment by giving written consent.

The inclusion criteria included having at least one previous bleeding episode and symptom and being treated in our clinic between January 2013 and December 2018. The patients with cavernomas who did not have bleeding and symptoms and those who were irradiated for other benign reasons (e.g. arteriovenous malformation), were excluded from the study. We did not treat any patient for whom we could not have MRI or pregnant patients, or those previously received external beam radiation or radiosurgery to the brainstem. Patients who were under a ventilator or whose severe symptoms had not yet resolved after bleeding were excluded from the study because they were not treated. We waited several weeks for a hemorrhage to reimage and after considering treatment.

Follow-up and primary and secondary endpoints

Patients were followed up using MRI [16] and neurologic examinations every 6 months for the first 2 years following the treatment. Yearly follow-ups continued with the same methods after the 3rd year. Radiologically, complete response (CR) referred to no cerebral cavernous malformations (CCMs), partial response (PR) referred to dimensional response $\geq 50\%$, stable disease (SD) referred to $< 50\%$ dimensional response, and progressive disease (PD) was any dimensional growth. Those with epileptic findings before treatment were neurologically evaluated using electroencephalography at regular intervals. The median follow-up period was 38 (IQR: 19–54) months. The presence of neurologic symptoms and signs together with new bleeding areas on MRI was defined as hemorrhage. The annual bleeding rate was found by dividing the patients with these findings by the total number of patients. The clinical and radiologic response was determined as the primary endpoint. As the secondary endpoint, the possible adverse effects (safety) that could have developed in association with this treatment were determined. Acute and late toxicity was evaluated with the Common Terminology Criteria for Adverse Events (CTCAE, version 5.0) [17]. For the patients' clinic, CR meant improvement of all clinical symptoms; PR was when patients' symptoms still existed, but more than half of these symptoms improved; SD was if there was no improvement in the patient's symptoms, meaning their condition is unchanged. PD, on the other hand, was where the patients' symptoms were further worsened.

Radiotherapy specifications

In our clinic, radiotherapy has been used for approximately 50 years, and all radiosurgery methods have been applied to cranial and extracranial regions for the last 10 years. In intracranial cavernomas, the CyberKnife[®] (Accuray Inc., Sunnyvale, CA, USA) radiosurgery system with 6-MV is used in all second-series cranial radiosurgery procedures because it provides patient compliance and comfort, does not require a rigid frame, can enable real-time tracking with 0.1-millimeter sensitivity, offers the possibility of applying fractional treatment when necessary, has almost no penumbra, does not require ITV margins, and provides dosimetric success in lesions below the size of 4 CCM as noncoplanar.

In all patients, immobilization was provided using a custom thermoplastic mask. The simulations of the patients were contoured using 1-mm CT and 1-mm T1-weighted Brava sequences under these conditions. The target volume (TV) was defined as the region of mixed-signal changes on MRI surrounded by hemosiderin rings. PTV margins were not used. Inverse planning was performed using the MultiPlan Treatment Planning System (Accuray) software. During treatment, real-time images were taken with R-ray cameras, and instant follow-up and corrections were made. A representative treatment plan of a patient is shown in Figure 1.

Statistical analysis

All time-related events (failure or death) were calculated from the date of the first SRS to the date of death or censoring at the last clinical follow-up and analyzed using the Kaplan–Meier and Cox proportional hazard methods. Significance was considered at $P < 0.05$, and all significance levels were two-sided. The IBM[®] SPSS[®] Statistics version 23

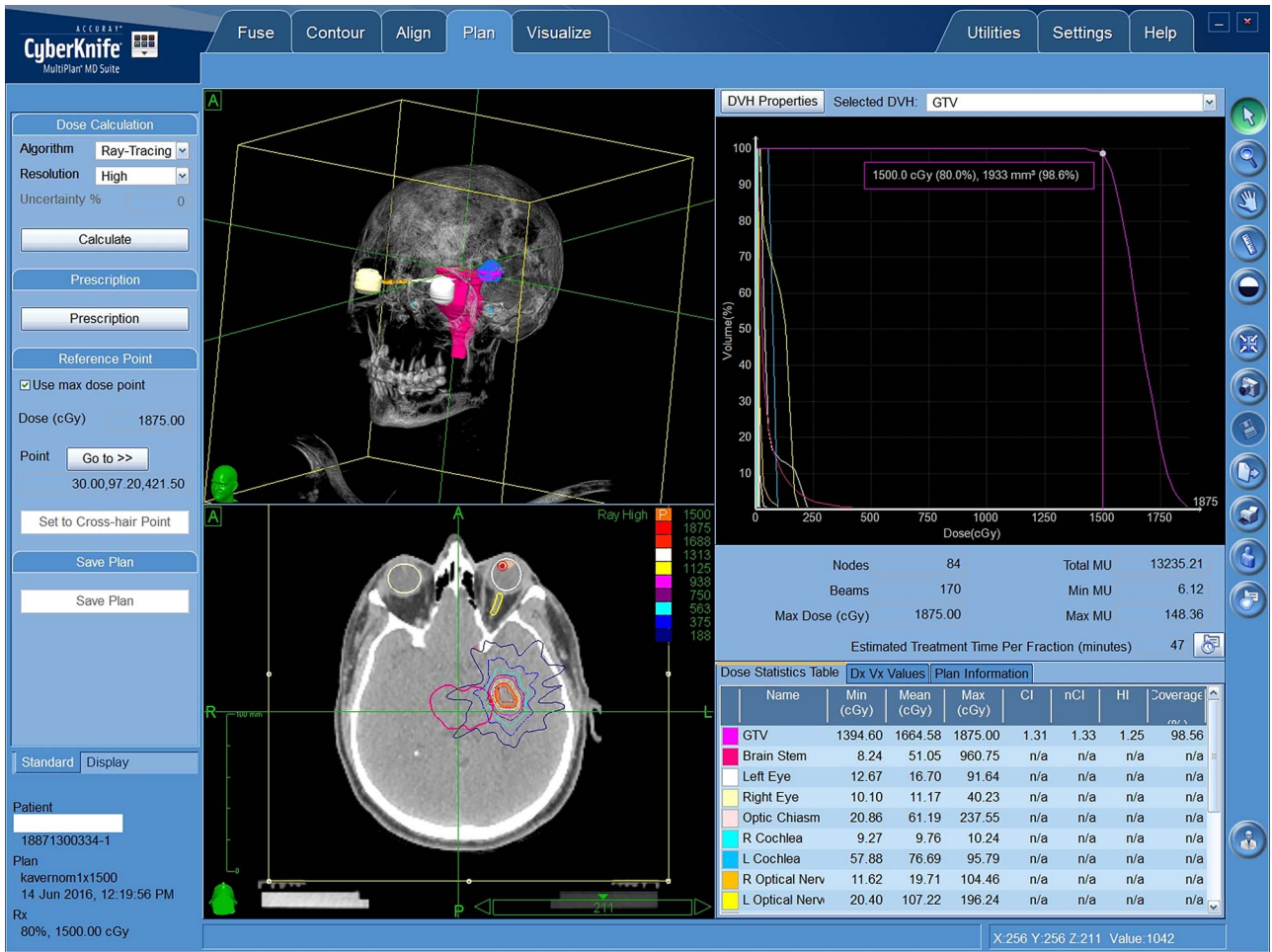


Fig. 1. Dose volume histogram for a patient with cavernoma.

software package was used for all statistical analyses. Logistic regression analyses was performed to determine the factors affecting edema pre-SRS.

RESULTS

The median Karnofsky performance status (KPS) was 90 (IQR: 60–100). Twelve (22.6%) patients had neurologic events (gait disturbance, double vision, loss of balance, dizziness, speech disorder). Two (3.8%) patients’ diseases were found incidentally. One of these patients had ovarian cancer, and the other had lung cancer, and their diseases were found during metastasis screening conducted with the prediagnosis of cranial brain metastasis. The patients’ cavernomas were deeply located or in the subcortical functional brain regions. The median dose was 15 (range, 14–16) Gy. BED₁₀ 37.5 Gy was administered in patients with more than one cavernoma (3 fractions 18 Gy, BED₁₀ 28.80 Gy). Isodose curves of 80–90% were used in all patients. Patient and disease characteristics are presented in Table 1.

During the follow-up, one patient had edema 8 months after the treatment and bleeding again in the twelfth month, and then this

patient underwent emergency surgery but died in the nineteenth month. Another patient died of a cardiac disorder that had begun 3 years before the treatment of the cavernoma. Although all patients had bleeding at least once before treatment, only two (4%) developed bleeding after treatment. Six (50%) of 12 patients with neurologic deficits still had neurologic deficits after treatment. Fourteen (60.9%) of 23 patients who received epilepsy treatment discontinued the drug completely, but in four (17.3%) of nine patients whose epilepsy was continuing, the dose of levetiracetam decreased from 2000 mg to 1000 mg. The patients were referred to us with epilepsy. In patients who have at least one CCM and there is evidence of a seizure onset zone in the immediate vicinity of the CCM and there is no evidence of other causes for epilepsy. For example, a patient with tonic-clonic seizures of the right hand and CCM of the left M1 (M2 back-up) hand region.

As a clinical response, CR was observed in 30 (56.6%) patients, PR was observed in 16 (30.2%), SD was observed in three (5.7%) and four (7.5%) patients developed PD. Adverse effects and treatment responses are presented in Table 2. The first MRI median was taken

Table 1. Summary of the patients' characteristics

Age (years)	48 (35–60)
Sex	
Male	23 (43.4%)
Female	30 (56.6%)
Duration of follow-up (months)	38 (19–54)
Symptoms	
Headache	16 (30.2%)
Incidental	2 (3.8%)
Epilepsy	23 (43.4%)
Other Neurologic symptoms	12 (22.6%)
Previous operation	
None	50 (94.3%)
Yes	3 (5.7%)
Localization	
Brain stem	5 (9.4%)
Frontal lobe	14 (26.4%)
Temporal lobe	5 (9.4%)
Occipital lobe	4 (7.5%)
Cerebellum	4 (7.5%)
Parietal	5 (9.4%)
Basal ganglia + deep-seated lesions	16 (30.2%)

Data are given as median (1st percentile – 3rd percentile) for continuous variables and as frequency (percentage) for categorical variables

for treatment response in the sixth month. However, the radiologic acquired median was obtained after two years.

We had five patients with CCM in the brainstem. The median TV was 1240 cc. The median dose was 14Gy/1frx. Areas of perihematoma and edema occurred in a patient with a 2606 cc TV as an acute adverse effect. Clinical and radiologic responses were obtained in all patients.

We had 16 patients with basal ganglia and deep-seated lesions. The median number of lesions was 1. The median volume was 824.5 (range, 437–2277) cc. The median dose was 15 (range, 14–16) Gy. Three patients developed acute adverse effects and one developed grade 3 edema (progressed after SRS). Intractable epilepsy was still present in five patients. In two patients, there was a CR, in whom drug use has been terminated. In one patient, there was a loss of upper motor neurons on EEG. Clinically, four patients progressed (CR: 9, PR: 1, SD: 2, PD: 4). Radiologically, two patients progressed (CR: 1, PR: 10, SD: 3, PD: 2). One patient in our cohort developed bleeding after 15 months. A patient with a CCM of 2265 cc underwent surgery for dense edema after 2.5 months after SRS. In seven of the 16 patients we treated, edema was still present in the first year. Neurologic deficits continue in four of our patients. Ten patients had edema pre-SRS, and post-SRS, only seven patients had ongoing edema in the first 1 year and two of these patients underwent surgery. Initially, four out of six patients with neurologic deficits had concomitant edema.

Many of our patients included had only bled once before. In the first year after SRS, one (2%) patient developed rebleeding. In the second year, one other patient developed rebleeding (2%). As a result, a total of two (4%) patients had rebleeding.

Table 2. Summary of the adverse effects and treatment response

Acute adverse effect	
None	49 (92.5%)
Yes	4 (7.5%)
Late adverse effect	
None	50 (94.3%)
Yes	3 (5.7%)
Clinical response	
CR	30 (56.6%)
PR	16 (30.2%)
SD	3 (5.7%)
PD	4 (7.5%)
Volume (mm³)	741 (421–1351)
RT dose (Gy)	15 (14–16)
Neurologic deficit	
None	47 (88.7%)
Yes	6 (11.3%)
Re-Hemorrhage	
None	51 (96.2%)
1st year	1 (1.9%)
2nd year	1 (1.9%)
Post-RT Epilepsy	
Yes	9 (39.1%)
Past	14 (60.9%)
Total	23 (100%)
Post-RT symptoms (with/without exception of edema and epilepsy) (e.g. neurologic deficit)	
None	44 (83%)
Yes	9 (17%)
Radiologic response	
CR	13 (24.5%)
PR	32 (60.4%)
SD	6 (11.3%)
PD	2 (3.8%)
Presence of rim still on MRI in the first year after SRS	
None	50 (94.3%)
Yes	3 (5.7%)

Data are given as median (1st percentile – 3rd percentile) for continuous variables and as frequency (percentage) for categorical variables.

Symptoms persisted in nine patients post-SRS, with or without epilepsy and edema. Four of these patients had deep-seated lesions. In the first patient, edema developed after 2.5 months, and in the tenth month, when the signs of edema worsened, the patient, who underwent surgical intervention, had a neurologic deficit on the right side of the body. In the second patient, the presence of diffuse edema, as well as epileptic attacks and severe headache remain unchanged. “The patient is still bedbound and unable to perform daily activities. The findings of epilepsy and edema improved in the third patient, but the headache and burning sensation persist. The fourth patient has upper motor neuron loss on EEG post-SRS. The fifth patient, on the other hand, had no improvement in the headache after treatment and remains unchanged.

Weakness and gait disturbance in the left leg persist in the sixth patient. The seventh patient has worsened with the development of dizziness. The patient had a pelvic fracture as a result of falling due to dizziness and required surgery. Bleeding developed in the eighth patient within the first year after treatment, and in the ninth patient within two years.

Adverse effects

In the acute phase, adverse effects developed in four (7.5%) patients. The first patient had grade 2 dizziness immediately after the treatment. The second patient, who had a 14 mm lesion located in the left sublentiform, developed grade 3 edema (worsened after treatment) 75 days after the treatment. The third patient, who had two lesions, both of which underwent SRS, had grade 2 edema (worsened). The patient, who had a 15 mm mass at the deep centrum semiovale frontal lobe level on the right and had epilepsy at baseline, also had worsened edema on the 70th day after SRS. In this patient, edema regressed 12 months after treatment, but he was still using epilepsy drugs. For the first week after SRS, four patients developed sensitivity to noise and sound and mild paraesthesia of the face, which was transient.

In the chronic period, adverse effects developed in three (5.6%) patients. One patient developed grade 2 weakness in the left leg and gait defect and vasogenic edema on cranial MRI. In another patient whose lesion in the mesencephalon was treated, edema worsened in the second month and focal neurologic deficits developed, low-dose corticosteroid treatment was administered, and the edema and deficit completely disappeared in the follow-up in the twelfth month. No new cavernoma foci emerged after SRS in any of the 53 patients during the follow-up.

Edema was observed pre-SRS in 10 (18.9%) patients, which disappeared in three patients in the first year. After the first 1 year of post-SRS, radiologic edema appearances continue in seven patients. One of them was grade 3 (worsened). This patient had worsened edema and hydrocephalus in the eighth month (third chronic period patient) and underwent surgery in the twelfth month but died in the nineteenth month. Another patient had two lesions and edema, but there was no regression in the patient's edema and epilepsy after the treatment (unchanged), and the patient's KPS, which was 60 before the treatment, decreased to 50. The edema of all other patients completely resolved in the twelfth month as an MRI finding. Five out of 10 patients improved but edema was still visible radiologically because responses to low-dose corticosteroids were in the basal ganglia and deep-seated. Again, the nonresponse rate to epilepsy occurred in lesions of this region with a rate of 62%. Radionecrosis was not observed in any patient. Details of re-SRS edema and post-RT epilepsy localizations are given in Table 3. Of the risk factors that may affect the development of edema, only the volume-edema relationship was found to be statistically significant (Table 4).

In one patient who underwent surgery for cavernoma 8 years before the treatment but had a recurrence, one of two treated lesions, which was treated at 1 fraction, completely disappeared radiologically. However, in the other lesion in the pons, which was treated at 3 fractions, one more bleeding event was observed in the following period. In one patient with edema and neurologic deficits, upper motor neuron loss was observed in the EEG.

DISCUSSION

There is a paucity of data regarding the appropriate treatment approach available in cavernomas with cranial eloquent placement. Symptomatic cavernomas in the eloquent region can have dramatic consequences if they are monitored without treatment [18]. The most feared adverse effects of cavernomas are bleeding and associated neurological events (or deficits), epilepsy, and even death. When untreated, the risk of rebleeding within the first 2.5 years after the first bleeding event is 2% per month and a cumulative 14% per year [9, 19]. In patients who have had bleeding twice before, the probability of occurrence of neurologic deficits and MRI findings due to rebleeding reaches up to 34–40% annually [10, 11, 20, 21]. Moreover, surgery may be restricted to hard-to-reach and eloquent regions of the brain [22]. Radiosurgery can be considered an option to avoid leaving lesions in this area untreated. However, there is currently no guideline based on a common consensus regarding the doses used or what effects radiosurgery could have in the short term in cavernoma radiosurgery. The doses prescribed for cavernomas are based on our experience in metastatic brain tumors in general. However, patients with cavernomas live much longer periods than these patients, and in this regard, we are likely to observe late (BED₂) radiobiologic adverse effects of SRS. However, there is no retrospective study or a phase 2 study related to this. In this regard, with a single homogeneous dose that is quite sufficient for cavernomas located in the eloquent region, both the effects of 15 Gy/1frx and the adverse effects of the short and late periods were revealed in great detail in a group of patients for the first time in our study.

Hemorrhage is one of the most common and feared clinical findings known because it causes various sequelae of hemorrhage in cavernoma. Although the effects of radiosurgery are not fully known, closure, endothelial cell proliferation and hyalinization result in luminal occlusion and thrombobliteration [23]. This explains the gradual decrease in bleeding rates over time [23]. There are studies in the literature reporting a risk of bleeding after surgery between 2.7% and 4% [24]. There is a study showing that it decreased to 8.8% in the first year and 1.1% in the second year after radiosurgery [25]. In our study, after treatment, one patient had bleeding in the twelfth month and underwent surgery but died in the nineteenth month. In another patient who had two cavernomas and underwent surgery 8 years ago for cavernoma, rebleeding occurred in the lesion in the pons, whereas the other lesion displayed CR (3.8%). Our rebleeding rate was very low compared with the literature [23]. As our results show, SRS is very promising in terms of preventing rebleeding. In cavernomas that had previously bled and had not received any treatment, the risk of rebleeding in the next 2.5 years was reported as 2% per month and cumulatively as 14% per year [9]. The probability of occurrence of neurologic deficits and MRI findings due to rebleeding reaches up to 34% annually in patients who have had bleeding twice previously [10, 11]. As a result, SRS is very promising as a preventive treatment for rebleeding and the development of neurological deficits in deep-seated lesions.

Nevertheless, it should be noted that the bleeding style of CCMs has been considered as clustering. Most CCMs have a temporary bleeding clustering period for the first few years and then move to relatively quiescent when the lesion rarely bleeds [9, 26]. Previous bleeding is an important risk factor for future hemorrhagic events [26]. For this reason, following this initial cluster of bleeding events, the no bleeding

Table 3. Pre-SRS edema and post-RT epilepsy with regard to localization

Localization	Pre SRS Edema			Pre SRS epilepsy (<i>n</i> = 23) Post-RT epilepsy (<i>n</i> = 9)		<i>P</i>
	None	Yes (<i>n</i> = 10)	<i>P</i>	Post SRS (still epilepsy) (<i>n</i> = 9)	Post SRS (no more epilepsy) (<i>n</i> = 14)	
Brain stem	4 (80%)	1 (20%)	0.013	0 (0%)	0 (0%)	0.209
Lobe	27 (96.4%)	1 (3.6%)		4 (28.6%)	10 (71.4%)	
Cerebellum	3 (75%)	1 (25%)		0 (0%)	1 (10%)	
Basal ganglia+deep-seated lesions	9 (56.3%)	7 (43.8%)		5 (62.5%)	3 (37.5%)	

According to the location of cavernomas, the formation of edema around it was statistically significant ($P = 0.013$). However, the location of cavernoma related to the continuation of post-SRS epilepsy was not found to be statistically significant ($P = 0.209$)

Table 4. Risk factors affecting edema

Variables	OR (95% CI)	<i>P</i> -value
Age, years	0.964 (0.914–1.016)	0.170
Sex		
Female	Reference	
Male	2.574 (0.419–15.800)	0.307
Volume, mm³	1.100 (1.000–1.200)	0.034

It was determined that every mm³ increase in volume increased the development of edema by 1.1 times.

post-SRS or disappearance of hematoma on MRI may result from the natural history of CMs rather than the effect of SRS.

No radionecrosis was observed in any of our patients, which is thought to be related to the technique we used. Generally, in eloquent regions, it is avoided because of the adverse effects that may occur. However, in CyberKnife® treatment of lesions in the brain region, 70–90% of isodoses surround the lesion and do not cause too much heating in the lesion. We think that this reduces the rate of adverse effects. Our results show that CyberKnife® use is very safe in cavernomas in terms of radionecrosis.

Microsurgical methods are primarily considered in cavernomas that require treatment. However, unfortunately, prospective randomized studies cannot be performed to show the effectiveness of SRS compared with surgery because surgery cannot be performed in these regions. However, when evaluated in terms of the treatment of epilepsy caused by cavernoma, both methods were found to be equal [27]. Even though CCM operations are performed in experienced centers, absolute morbidity is reported afterward even with favorable localization [28]. Moreover, it has been shown in a recent prospective study that CCM excision worsened short-term disability and increased the risk of neurologic deficit or recurrent bleeding [29]. However, in our study, it is not possible to mention any serious morbidity related to SRS. SRS is considered as a non-invasive and highly beneficial treatment option for cavernoma treatment.

We usually have the first follow-up MRI taken in the sixth month in patients. However, due to the mechanism of action of cavernoma radiosurgery, the median radiologic response is achieved approximately in the second year. There is no reliable imaging biomarker for successful

cavernoma obliteration, as is the case with metastases and high-flow vascular lesions [30]. In many studies, a latency period after SRS is mentioned. Hasegawa *et al.* [31] showed that bleeding rates decreased from 33% to 12% two years after eloquent regional SRS and that annual bleeding rates decreased below 1% after two years. These results are parallel to our study. In our study, our bleeding rates were 2% for the first two years, but we did not detect bleeding in any patients after the second year.

Epileptic seizures are seen in patients with bleeding depending on the location. Generally, neurologic events are mentioned during bleeding [32]. Of the patients included in our study, 23 had epilepsy. Fourteen of these patients (60.9%) discontinued the drug that was used, and the dose was reduced in four (17.3%) of nine patients. Gao *et al.* [33] found that the seizure control rate was 79% for neurosurgery and 49% for radiosurgery. However, our total seizure control rate was 78.2% in these patients, who we followed as a single center. This is similar to the neurosurgery results in the meta-analyses by Gao *et al.* and better than their radiosurgery results. That is, radiosurgery is very effective in the treatment of cavernoma-related epilepsy, in the complete withdrawal or reduction of the drug. However, a relationship between lesions in the temporal region and epilepsy has been reported [34]. But in our study, we observed seizures that we could not control, especially in the basal ganglia and deep-seated lesions. A total of 62.5% of epilepsies in this region could not be fully controlled. Although our success rate of epilepsy treatment in the basal ganglia and deep-seated regions was 37.5%, it is considered clinically significant that we achieved 71.4% success in lobe epilepsies, even though we did not achieve statistical significance. However, it should be remembered that the 78.2% success rate we achieved with EEG in total is a non-invasive method and is quite promising for a method that causes almost no morbidity after treatment. Usually, discontinuation of epilepsy medications in patients was observed on MRI after an average of the second year in parallel with the reduction or disappearance of cavernomas and the hemosiderin fringe. Another patient of ours, who previously took levetiracetam twice per day, is now being considered to stop using the drug because her EEG, which was taken during sleep, became normal after we ended the study.

When all publications are examined [35], the majority of publications are with the Gamma Knife® (88%), whereas CyberKnife® treatment of lesions in the brain region, in eloquent regions, is avoided because of the adverse effects that may occur. SRS is a relatively new

radiosurgical method for cavernomas and stands out at a very low rate (2%). There is no difference between SRS treatments performed with a Gamma Knife and linear accelerator SRS, but there is no such study for Cyberknife® [36]. However, as seen in our study, CyberKnife® radiosurgery can successfully treat all eloquent regions and seems at least equal to other radiosurgery applications in terms of all clinical results of the treatment. For this reason, we prefer CyberKnife® in the treatment of cavernomas, which is our daily practice. We used other radiosurgery methods mostly in extracranial areas.

As seen in meta-analyses [35], few results have been reported in cavernomas with deep, eloquent, or even brainstem localization. Moreover, it is very difficult or even impossible to surgically intervene in the lesions we treat. Furthermore, as a result of many randomized [37, 38] and nonrandomized [39] studies, it has been shown that the clinical results of radiosurgery applications and neurosurgery methods are not different. Accordingly, radiosurgery, which is a much more reliable method in terms of adverse effects, should be used instead of neurosurgery in eloquent localized cavernomas, as discussed below.

Follow-up of the clinical response is very important in this disease. However, in cavernomas, the follow-up of the radiological response is not as important as it is in tumors. Providing stability is quite sufficient. The importance of radiology is that it can be used in the close follow-up of patients for the detection of progressed disease, new bleeding and adverse effects such as hydrocephalus and radionecrosis.

Basal ganglia and deep-seated localization were found to be statistically significant in terms of the occurrence of edema pre-SRS ($P=0.003$). We think this may be related to the increase in blood supply in this area; obviously, we do not know the exact cause. However, for this reason, simultaneous and adjuvant cortisone can be administered in the treatment of this region. Although there is no literature in this regard, care should be taken in terms of edema in SRS applications in the basal ganglia and deep-seated regions.

Studies have shown that supratentorial lobar CCMs have a much more benign prognosis than deep lesions of the thalamus, basal ganglia, or posterior fossa. In one study, the incidence rate for superficial lesions was 0% per year, whereas, for deep lesions, this rate was 10.6% per year [26, 40]. The vast majority (35–70%) of all cerebral hemorrhages occur in the basal ganglia and deep-seated localizations [41]. Although, as can be seen from the literature, deep-seated areas are the most common areas that tend to rebleed, most are inoperable. However, in our study, bleeding was observed 15 months after SRS treatment in only one (6.25%) patient with a CM located in this region. This result shows how vital the application of SRS is, especially for the basal ganglia and deep-seated CMs, a region that has a high incidence of rebleeding, a high risk of morbidity, and death, if bleeding develops and is difficult to reach surgically.

Brainstem CCMs are the most dangerous and have a high relative incidence (four to seven times more likely to rupture than isolated supratentorial lesions). In a meta-analyses, non-brainstem bleeding rates for brainstem lesions were reported as 0.3% vs 2.8% per year [42, 43]. Initial presentation of patients with bleeding or focal neurologic deficit and brainstem location was associated with hemorrhage independently for 5 years after the initial diagnosis [26, 44]. In our patients' follow-ups, no complications developed in a patient other than perihematoma and edema in the acute period. However, as can be seen from our treatments, they were quite large volume lesions.

Taken together, it can be seen, in accordance with our results, how vital a role SRS can play in this region, which is often seen as a 'no fly zone' in terms of surgery, even though it does not contain neural tissue. Although some studies have claimed that there may be quite devastating adverse effects of SRS in areas such as the brainstem, no serious adverse effects were seen in any patients due to brainstem location in our study [45]. Moreover, we should not forget that with the developing SRS technology, we are treating metastatic brain stem lesions safely today, even with higher doses than we used in cavernomas [15]. In malignant lesions, we define the dose not to the wall, but the 95% isodose line [15]. It should be remembered that the complication rates are quite high when lesions in the brainstem are removed even in experienced centers. Neurologic deficits were observed in 53% of patients after these operations [43]. This indicates the importance of applying SRS to eloquent brain regions in experienced centers.

Treatment of lesions in the brain region, especially in eloquent regions, is avoided because of the adverse effects that may occur. Therefore, invasive methods such as surgery are feared by both physicians and patients. Moreover, even systematic meta-analyses in radiosurgery have been performed with a very limited number of patients [30]. Outcomes can be devastating in patients who are left untreated, along with hemorrhage. However, as seen in our study, there is a very acceptable toxicity rate at the doses we use; therefore, it is a very cost-effective treatment method.

Adverse effects

As an adverse effect, an increase in the existing edema may be observed. For this reason, caution should be taken when treating basal ganglia and deep-seated lesions with SRS, the most frequent sites of edema in our study. Prophylactic low-dose corticosteroid maintenance should be administered in such lesions. Our median dose of 15 (range, 14–16) Gy, which we applied to our patients, was decreased to 13 Gy and below in the literature. It can be thought that this would reduce the adverse effect of worsened edema. Although publications are stating that SRS can have adverse effects substantially often [30], with today's technology, even if the cavernoma is eloquent in location, single-dose radiosurgery is very effective and has tolerable adverse effects.

It has been suggested that SRS is strongly linked to the development of new cavernomas [46]. In our study, no new cavernoma foci were observed 53 patients in our follow-up, including the patient who underwent surgery in 2009 and underwent SRS in 2017 after developing a new lesion.

Limitations

This study is a retrospective study. After beginning to study the follow-ups, regular follow-ups of the patients by a single physician were conducted with the help of the radiology unit for 2 years. To reduce the occurrence of bias due to its retrospective design, all patients who had bleeding before and who had symptoms were included in the study. However, our study population included homogeneously treated patients concerning the SRS total dose, dose per fraction and fractionation. SRS total doses have been extrapolated from other vascular malformation and/or brain metastases reports as being effective and safe regimens, but there are no firm data to support its use for anywhere cavernous malformations. Although relatively low marginal doses are

applied compared with malignant tumors, the optimum treatment dose remains uncertain [47]. Therefore, it is thought that this study, which used a fairly homogeneous dose, considering the number of cases, will contribute to the formation of the literature [48].

CONCLUSION

With developments in radiosurgery, highly sophisticated treatments can be performed. Successful results can be achieved for cavernomas with symptoms that are not considered suitable for surgery, and dramatic improvements in bleeding and seizure rates can be provided. Considering quite reasonable adverse effects, these patients should not be left untreated, and their treatment should be performed with SRS.

CONFLICT OF INTEREST

All authors declare no conflicts of interest related to this article.

REFERENCES

1. Raychaudhuri R, Batjer HH, Awad IA. Intracranial cavernous angioma: a practical review of clinical and biological aspects. *Surg Neurol* 2005;63:319–28 discussion 28.
2. Gil-Nagel A, Wilcox K, Stewart J et al. Familial cerebral cavernous angioma: clinical analysis of a family and phenotypic classification. *Epilepsy Res* 1995;21:27–36.
3. Labauge P, Laberge S, Brunereau L et al. Hereditary cerebral cavernous angiomas: clinical and genetic features in 57 French families. *Societe Francaise de Neurochirurgie. Lancet* 1998;352:1892–7.
4. Sheen JJ, Lee DH, Lee DH et al. Long-term outcome of gamma knife radiosurgery for brain cavernoma: factors associated with subsequent De Novo Cavernoma formation. *World Neurosurg* 2018;120:e17–23.
5. Akers A, Al-Shahi Salman R, Awad IA et al. Synopsis of guidelines for the clinical Management of Cerebral Cavernous Malformations: consensus recommendations based on systematic literature review by the Angioma alliance scientific advisory board clinical experts panel. *Neurosurgery* 2017;80:665–80.
6. Al-Shahi R, Bhattacharya JJ, Currie DG et al. Prospective, population-based detection of intracranial vascular malformations in adults: the Scottish intracranial vascular malformation study (SIVMS). *Stroke* 2003;34:1163–9.
7. Kida Y, Hasegawa T, Iwai Y et al. Radiosurgery for symptomatic cavernous malformations: a multi-institutional retrospective study in Japan. *Surg Neurol Int* 2015;6:S249–57.
8. Awad I, Jabbour P. Cerebral cavernous malformations and epilepsy. *Neurosurg Focus* 2006;21:1–9.
9. Barker FG 2nd, Amin-Hanjani S, Butler WE et al. Temporal clustering of hemorrhages from untreated cavernous malformations of the central nervous system. *Neurosurgery* 2001;49:15–24.
10. Chang SD, Steinberg GK, Levy RP et al. Microsurgical resection of incompletely obliterated intracranial arteriovenous malformations following stereotactic radiosurgery. *Neurol Med Chir (Tokyo)* 1998;38:200–7.
11. Karlsson B, Kihlstrom L, Lindquist C et al. Radiosurgery for cavernous malformations. *J Neurosurg* 1998;88:293–7.
12. Mouchtouris N, Chalouhi N, Chitale A et al. Management of cerebral cavernous malformations: from diagnosis to treatment. *Sci World J* 2015;2015:1–8.
13. Yuen J, Whitfield PC. Brainstem cavernous malformations - no longer a forbidden territory? A systemic review of recent literature. *Neurochirurgie* 2020;66:116–26.
14. Samii M, Eghbal R, Carvalho GA et al. Surgical management of brainstem cavernomas. *J Neurosurg* 2001;95:825–32.
15. Berber T, Raturi V, Aksaray F et al. Clinical outcome after CyberKnife® radiosurgery re-irradiation for recurrent brain metastases. *Cancer/Radiothérapie* 2021;25:457–62.
16. Requena I, Arias M, Lopez-Ibor L et al. Cavernomas of the central nervous system: clinical and neuroimaging manifestations in 47 patients. *J Neurol Neurosurg Psychiatry* 1991;54:590–4.
17. Atkinson TM, Ryan SJ, Bennett AV et al. The association between clinician-based common terminology criteria for adverse events (CTCAE) and patient-reported outcomes (PRO): a systematic review. *Support Care Cancer* 2016;24:3669–76.
18. Ciurea AV, Nastase C, Tascu A et al. Lethal recurrent hemorrhages of a brainstem cavernoma. *Neurosurg Rev* 2007;30:259–62.
19. Isamat F, Conesa G. Cavernous angiomas of the brain stem. *Neurosurg Clin N Am* 1993;4:507–18.
20. Abila AA, Turner JD, Mitha AP et al. Surgical approaches to brainstem cavernous malformations. *Neurosurg Focus* 2010;29:E8.
21. Kupersmith MJ, Kalish H, Epstein F et al. Natural history of brainstem cavernous malformations. *Neurosurgery* 2001;48:47–54.
22. Hauck EF, Barnett SL, White JA et al. Symptomatic brainstem cavernomas. *Neurosurgery* 2009;64:61–71.
23. Gewirtz RJ, Steinberg GK, Crowley R et al. Pathological changes in surgically resected angiographically occult vascular malformations after radiation. *Neurosurgery* 1998;42:738–41.
24. Sandalcioğlu I, Wiedemayer H, Secer S et al. Surgical removal of brain stem cavernous malformations: surgical indications, technical considerations, and results. *J Neurol Neurosurg Psychiatry* 2002;72:351–5.
25. Kondziolka D, Lunsford LD, Flickinger JC et al. Reduction of hemorrhage risk after stereotactic radiosurgery for cavernous malformations. *J Neurosurg* 1995;83:825–31.
26. Ellis JA, Barrow DL. Supratentorial cavernous malformations. *Handb Clin Neurol* 2017;143:283–9.
27. Hsu P-W, Chang C-N, Tseng C-K et al. Treatment of epileptogenic cavernomas: surgery versus radiosurgery. *Cerebrovasc Dis* 2007;24:116–20.
28. Gross BA, Batjer HH, Awad IA et al. Brainstem cavernous malformations: 1390 surgical cases from the literature. *World Neurosurg* 2013;80:89–93.
29. Moultrie F, Horne MA, Josephson CB et al. Outcome after surgical or conservative management of cerebral cavernous malformations. *Neurology* 2014;83:582–9.
30. Lu XY, Sun H, Xu JG et al. Stereotactic radiosurgery of brainstem cavernous malformations: a systematic review and meta-analysis. *J Neurosurg* 2014;120:982–7.
31. Hasegawa T, McInerney J, Kondziolka D et al. Long-term results after stereotactic radiosurgery for patients with cavernous malformations. *Neurosurgery* 2002;50:1190–7.

32. Kida Y. Radiosurgery for cavernous malformations in basal ganglia, thalamus and brainstem. In: *Japanese Experience with Gamma Knife Radiosurgery*. Basel: KARGER, 2008, 31–7.
33. Gao X, Yue K, Sun J et al. Treatment of cerebral cavernous malformations presenting with seizures: a systematic review and meta-analysis. *Front Neurol* 2020;11. <https://doi.org/10.3389/fneur.2020.590589>.
34. Menzler K, Chen X, Thiel P et al. Epileptogenicity of cavernomas depends on (archi-) cortical localization. *Neurosurgery* 2010;67:918–24.
35. Poorthuis MH, Rinkel LA, Lammy S et al. Stereotactic radiosurgery for cerebral cavernous malformations: a systematic review. *Neurology* 2019;93:e1971–e9.
36. Kim D, Choe W, Paek S et al. Radiosurgery of intracranial cavernous malformations. *Acta Neurochir* 2002;144:869–78.
37. Frischer JM, Gatterbauer B, Holzer S et al. Microsurgery and radiosurgery for brainstem cavernomas: effective and complementary treatment options. *World Neurosurg* 2014;81:520–8.
38. Shih Y-H, Pan DH-C. Management of supratentorial cavernous malformations: craniotomy versus gammaknife radiosurgery. *Clin Neurol Neurosurg* 2005;107:108–12.
39. Kayali H, Sait S, Serdar K et al. Intracranial cavernomas: analysis of 37 cases and literature review. *Neurol India* 2004;52:439.
40. Porter PJ, Willinsky RA, Harper W et al. Cerebral cavernous malformations: natural history and prognosis after clinical deterioration with or without hemorrhage. *J Neurosurg* 1997;87:190–7.
41. Aguilar MI, Brott TG. Update in intracerebral hemorrhage. *Neurohospitalist* 2011;1:148–59.
42. Taslimi S, Modabbernia A, Amin-Hanjani S et al. Natural history of cavernous malformation: systematic review and meta-analysis of 25 studies. *Neurology* 2016;86:1984–91.
43. Abla AA, Lekovic GP, Turner JD et al. Advances in the treatment and outcome of brainstem cavernous malformation surgery: a single-center case series of 300 surgically treated patients. *Neurosurgery* 2011;68:403–14.
44. Horne MA, Flemming KD, Su IC et al. Clinical course of untreated cerebral cavernous malformations: a meta-analysis of individual patient data. *Lancet Neurol* 2016;15:166–73.
45. Atwal GS, Sarris CE, Spetzler RF. Brainstem and cerebellar cavernous malformations. *Handb Clin Neurol* 2017;143:291–5.
46. Nimjee SM, Powers CJ, Bulsara KR. Review of the literature on de novo formation of cavernous malformations of the central nervous system after radiation therapy. *Neurosurg Focus* 2006;21:1–6.
47. Kim BS, Kim KH, Lee MH et al. Stereotactic radiosurgery for brainstem cavernous malformations: an updated systematic review and meta-analysis. *World Neurosurg* 2019;130:e648–e59.
48. Orlev A, Feghali J, Kimchi G et al. Neurological event prediction for patients with symptomatic cerebral cavernous malformation: the BLED2 score. *J Neurosurg* 2022;68:93–4.