

Results of the 4-5 ECA vascularized pedicle bone grafting in avascular pseudoarthroses of the scaphoid proximal pole

Abdulkadir Sari¹, Bulent Ozcelik²

ABSTRACT

Objective: The scaphoid bone is the most injured carpal bone and is the cause of severe wrist dysfunction seen in nonunion cases. The probability of avascular necrosis is very high especially in fractures of the proximal pole, due to the retrograde blood flow in the region. In these cases, vascularized pedicle bone grafts, with high rates of union, is a good alternative to the conventional techniques. In this study, we present the results of vascularized bone grafting with grafts harvested from the 4-5 extensor compartment artery (ECA) and fixation with the Herbert screw in patients with avascular pseudoarthroses of the scaphoid proximal pole.

Methods: Fifteen patients who presented to our clinic due to nonunion of the scaphoid and who were applied vascularized pedicle bone grafts harvested from the ECA between 2006 and 2015 were included in the study. The mean age of the patients was 30.1 (19-42) and all patients were male. Patients were followed up for an average period of 22.7 (18-56) months. Union in the patients were evaluated with the preoperative and postoperative wrist ranges of motion. VAS (visual analog scale) and, for functional evaluation, the Turkish version of the Quick-DASH scale were used.

Results: Union was achieved in all patients after a mean period of 8.2 (6-10) weeks. The most significant improvements after surgery were detected in the VAS and functional Quick-DASH scores. No significant improvement was observed in wrist contractures. Other than the hematoma in one patient, no complication was observed.

Conclusion: In cases of nonunion of the scaphoid proximal pole fractures accompanied by avascular necrosis, pedicle grafts from the 4-5 ECA offer high rates of union and improvement in the pain and functional scores of the patients. Level of evidence Level IV, therapeutic study.

Key words: Vascularized pedicle bone graft, extensor compartment artery, pseudoarthroses, proximal pole, scaphoid

Introduction

The scaphoid bone is the most injured bone among all carpal bones. The development of severe wrist dysfunction in malunion and nonunion of the scaphoid

fractures points out to the importance of the scaphoid in biomechanics of the wrist. The rate of nonunion in displaced scaphoid fractures may go as high as 55% [1]. The probability of avascular necrosis is very high

Author affiliations : ¹Department of Orthopaedics and Traumatology, Namik Kemal University School of Medicine, Tekirdag, Turkey ²IST-EL Hand Surgery, Microsurgery and Rehabilitation Group, Gaziosmanpaşa Private Hospital, Istanbul, Turkey

Correspondence : Abdulkadir Sari, MD, Department of Orthopaedics and Traumatology, Namik Kemal University School of Medicine, Tekirdag, Turkey
e-mail: drortopedist@yahoo.com

Received / Accepted : January 13, 2019 / April 26, 2019

especially in fractures of the proximal pole, due to the retrograde blood flow in the region [2]. Vascularized pedicle bone grafts (VPBG) are often preferred over the conventional techniques in treatment of avascular necrosis [3,4].

In this study, we present the results of vascularized bone grafting with grafts harvested from the 4-5 ECA and fixation with the Herbert screw in patients with avascular pseudoarthroses of the scaphoid proximal pole.

Patients and Methods

Fifteen proximal pole avascular necrosis patients out of the 40 patients who had presented to our clinic

due to nonunion of the scaphoid between the years 2006 and 2015 and whose medical records could be accessed were included in the study. The mean age of the patients was 30.13 (19-42) and all patients were male. The mean time between the trauma and presentation was 17 (9-42) months. The patients were followed up for 22.73 (18-56) months on average (Table 1).

Eleven patients had not received any treatment previously. Six of them was not aware that they had a fracture until their admission to our clinic. The remaining four patients had been treated with plaster application for 6 to 8 weeks. All patients were evaluated with direct X-rays and MRIs (Figures 1A,1B,1C). Displacement of the fracture line was observed in 11 cases. Following the evaluation with MRI, all patients were diagnosed with avascular necrosis of the proximal pole. None of the patients showed carpal instability. Two cases had a history of smoking.

All patients were performed pedicle bone grafts harvested from the 4-5 ECA and stabilization was

Table 1. Patient characteristics (n = 15).

Mean age	30.13 (19-42)
Mean presentation time (month)	17 (9-42)
Mean duration follow-up (month)	22.73 (18-56)
Displacement of fracture line (n)	11
Smoker (n)	2

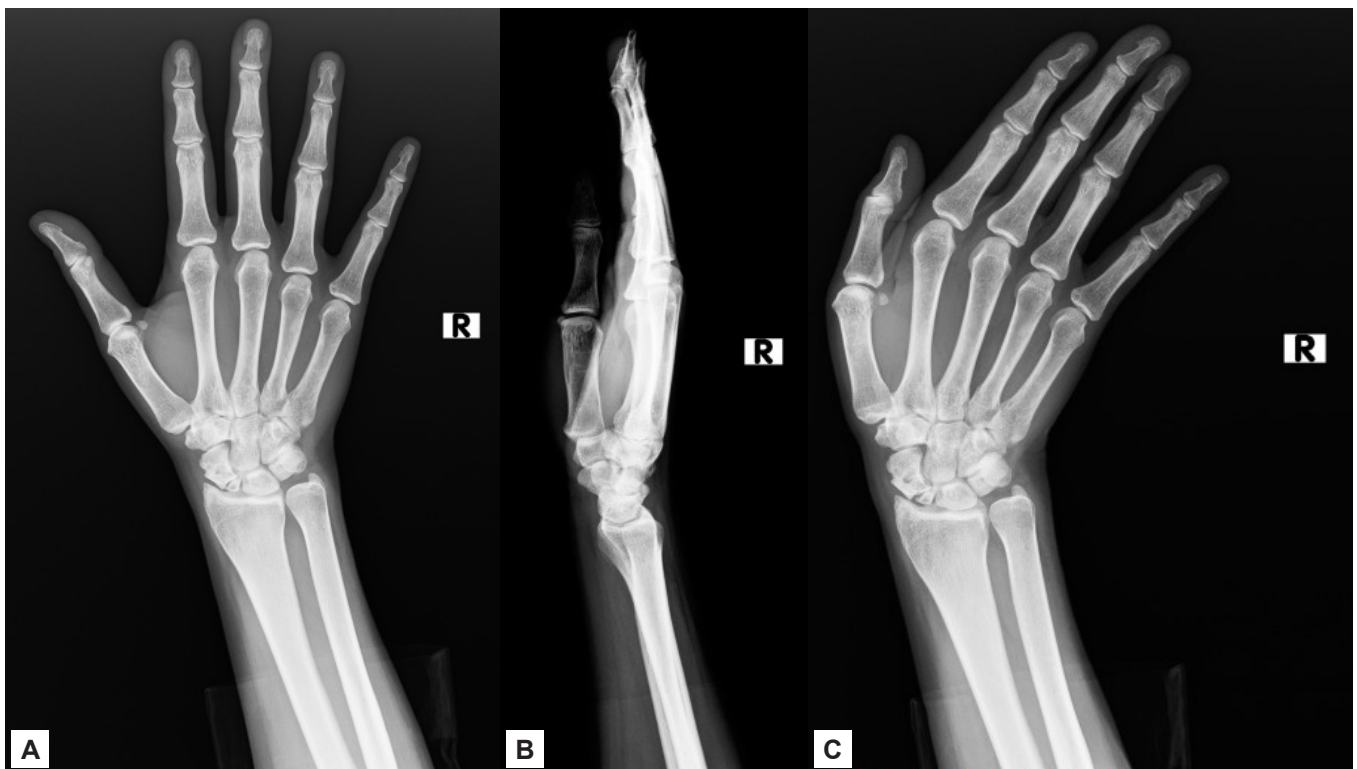

Figure 1A,1B,1C. Preoperative X-ray images. H.D, 35 year-old.

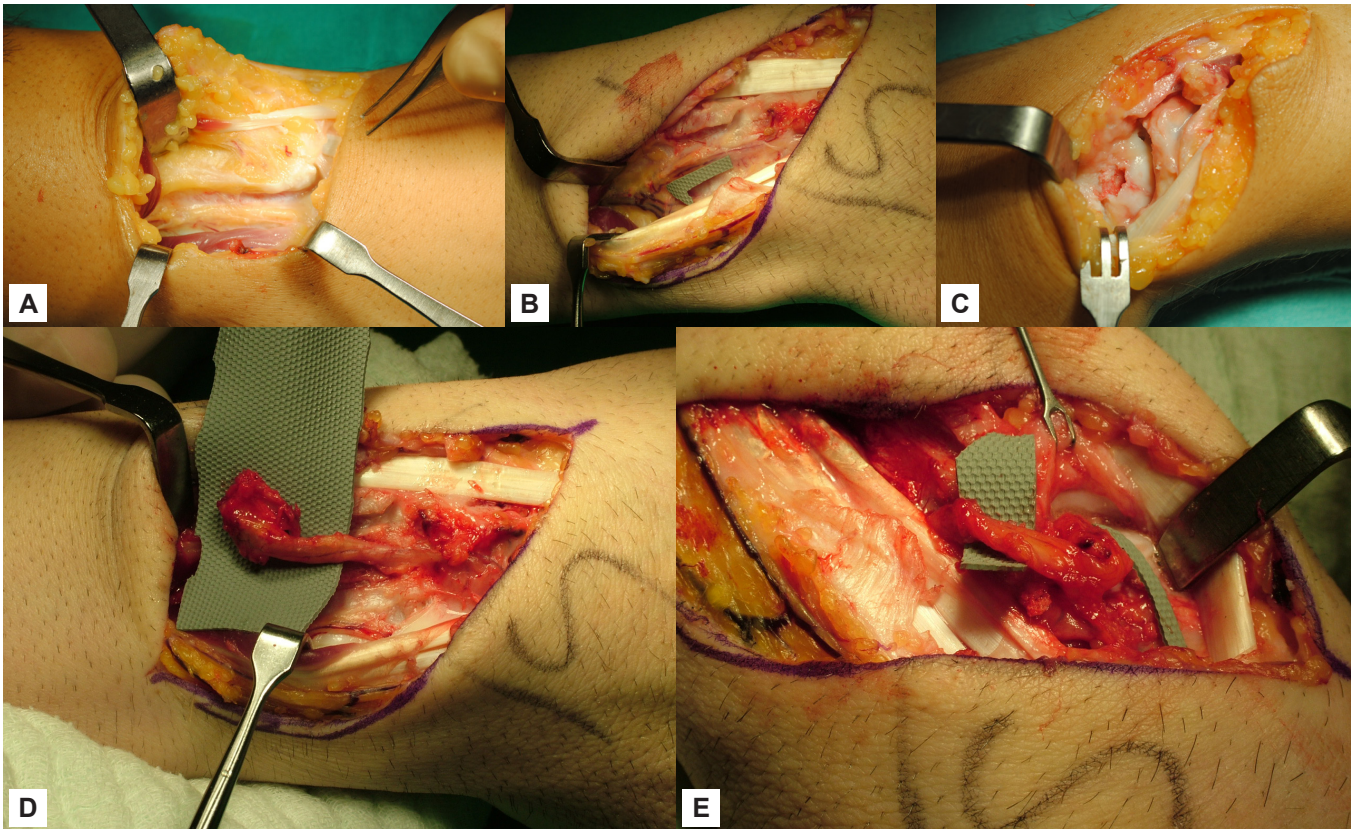


Figure 2. (A) Dorsal S incision and exposure (B) Transposition of the EPL and visualization of the extensor compartmental arteries (C) Curettage of the avascular scaphoid site (D) Preparation of the 4-5 ECA vascularized bone graft (E) Placing the graft on the scaphoid.

achieved with the Herbert screw.

In the postoperative evaluation of the patients, we used the degree of contracture instead of range of motion. VAS (visual analog scale) and, for functional evaluation, the Turkish version of the Quick-DASH scale were used.

The SPSS statistical software package was used in statistical analysis of the data to be obtained from the patients included in the study. Variables were expressed as frequency, percentage, mean (arithmetic mean and median) and standard deviation (min-max).

The study protocol was approved by the Institutional Review Board of our hospital. All patients signed an informed consent form.

Surgical Technique

All patients were operated by the same senior surgeon under axillary block anesthesia. The extremity was only elevated for visualization of the arteries dur-

ing surgery. No Esmarch bandage was applied. An S incision was made over the dorsal aspect of the wrist (Figure 2A). The EPL was preserved following the entry over the 3rd extensor compartment and the radius was reached after elevating the 4th extensor compartment (Figure 2B). The capsule was crossed to reach the scaphoid pseudoarthrosis site. Curettage and debridement of the avascular fragment were performed using a curette, a drill and a rongeur (Figure 2C). The 4th ECA was identified. The junction of the 4th ECA with the 5th ECA in the proximal was vascularized and was elevated toward the 4th ECA according to the base bone grafting technique (Figure 2D). Multiple holes were opened in the bone donor site using K-wires. Bone graft was harvested using a mini saw and an osteotome. A vascularized bone graft from the dorsal radius transposed onto the defect. After the elevation of the 4th and 5th ECA, the bone graft could easily get in contact with the prox-

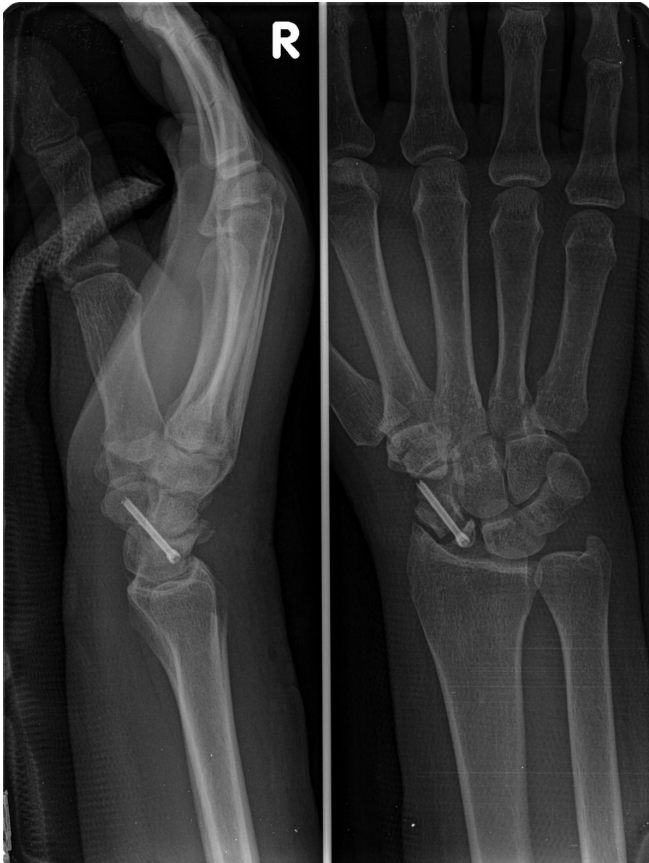

Figure 3. Postoperative early X-ray image. H.D, 35 year-old.

imal pole (Figure 2E).

The pedicle bone graft placed between the fractured fragments was temporarily fixed using 2 K-wires. Drilling was performed accordingly and permanent fixation was achieved with the Herbert screw (Figure 3). The Herbert screw was applied using an image intensifier via the free-technique and without the use of a jig. The dorsal capsule was closed after the operation. Patients were applied a short arm plaster cast, keeping their arms in the 'wine glass-holding' position. Union was observed in the follow-up radiographs and the patients were given a physical therapy program (Figures 4, 5). The patients were asked to refrain from performing forceful movements with their wrists for a period of 6 months.

Results

X-ray images confirmed union in all patients after a mean period of 8.2 (6-10) weeks.

The mean preoperative Quick-DASH symptom

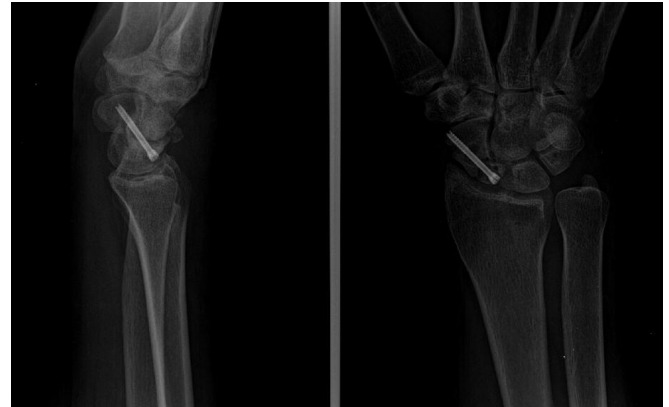


Figure 4. Postoperative image 6 weeks later. H.D, 35 year-old.

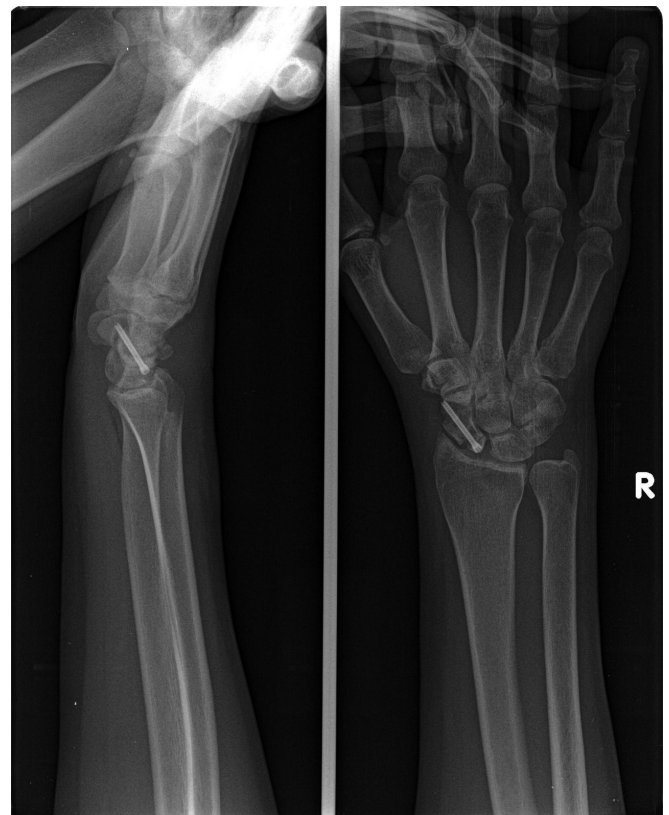


Figure 5. Postoperative image 1 year later. H.D, 35 year-old.

score of 42.26 (range: 22.7-65.9) receded to 7.26 (range: 2.3-11.4) postoperatively.

The mean VAS score was 6.92 (range: 5-9.2) before surgery and was 1.99 (range: 0.3-4.2) after surgery, showing an improvement of 71.2%.

In the postoperative evaluation of the patients, we used the degree of contracture instead of range of motion.

The mean preoperative extension contracture was 14.33 (35-0) degrees whereas it was measured 11.33 (30-0) degrees postoperatively.

Preoperatively, the mean flexion contracture was 4.66 (20-0) degrees while it was 2.66 (10-0) degrees after surgery.

The casts were removed after an average of 6 weeks and the patients could return to work after a mean period of 4.6 (3-7) months.

No complication was observed other than a hematoma seen in one patient.

Discussion

Nonunion of the scaphoid accompanied by avascular necrosis is one of the challenging issues of hand surgery. The fact that the patient population is often composed of young and active individuals makes avascular necrosis of the scaphoid an important socioeconomic problem [5,6].

Tolerability of the symptoms after scaphoid fractures, the challenges and failures experienced during the diagnosis in the early term lead to the failure of the fracture treatment and nonunion. Rates of nonunion up to 15% following scaphoid fractures have been reported [7]. The risk factors that contribute to nonunion are fracture displacement, delays in treatment, location (proximal pole), smoking and concurrent carpal instabilities [8]. In our study, 73% of the cases had avascular necrosis and nonunion subsequent to a displaced fracture. Two patients had a history of smoking.

Conventional grafts (non-vascularized bone graft-NVBG), free bone grafts and pedicle bone grafts can be utilized in scaphoid nonunions. Various types of vascularized bone grafts (VBGs) have been defined in the literature, including pedicle graft of the pronator quadratus, pedicle graft from the ulnar artery or palmar carpal artery, fasciosteal graft of the radial styloid, pedicle grafts of the 1st and 2nd metacarpals and distal radius grafts with a capsular pedicle. In addition to the pedicle grafts, vascularized free grafts can also be harvested from the iliac crest and medial femoral supra-

condylar region [9].

Vascularized pedicle grafts of the dorsal radius (VPGDR) which are widely used today were first introduced by Zaidenberg in 1991 [10]. Four major arteries can be used for VPGDR; 1,2 ICSRA (intercompartmental supraretinacular artery), 2,3 ICSRA, 4th ECA and 5th ECA [11].

Despite the ease of applicability of the conventional grafts, low rates of union in avascular necrosis cases and technical challenges in free bone grafts put VPBGs ahead. In the absence of avascular necrosis, union rates of 80-90% can be achieved with the use of NVBGs [12]. In a recent meta-analysis, NVBGs have reached a success rate of 47% in cases with avascular necrosis of the proximal pole. The success rate with the use of vascularized grafts reached 88% as reported in the same study [13]. Ribak et al. obtained worse functional outcomes with the use of non-vascularized grafts in the presence of avascular necrosis of the proximal pole. In the same study, a union rate of 90.5% was achieved with the use of VBGs in proximal AVN whereas the rate decreased to 68.9% with the use of NVBG [14]. This may be explained with the biological and mechanical superiority of the vascularized bone grafts to the conventional bone grafts. In the vascularized technique, the graft retains its strength and shape; remodeling is minimal [15]. Bone consolidation is rapid and requires shorter time of cast application in the postoperative period [16]. In particular, scaphoid fractures accompanied by avascular necrosis of the proximal pole, cases with a smaller proximal pole, and previous unsuccessful surgeries are appropriate indications for VPBG applications [11]. In our series, union was achieved in all patients who were applied 4-5 ECA grafts.

The 4-5 ECA graft combination, which is widely used in Kienbock's disease, has a long pedicle, and thus, easily extends to the proximal pole of the scaphoid [11]. The widest pedicle artery in the dorsal radius is the 5th ECA. However, as it lacks the branches that will

supply blood to the bone, it is joined with the 4th ECA. Its pedicle length and arterial diameter puts it forward in proximal nonunions of the scaphoid [17].

Özalp et al. reported union only in one of the nine proximal nonunion cases to whom they applied grafts from the 4-5 ECA and headless screws, and mentioned about the need for studies with larger series [18].

In general, the 4th and 5th ECA stand close to each other along the interosseous gap. No additional exploration was required for the operation. The 4th and 5th ECA were ligated at the proximal of the bifurcation in the intraosseous gap and were separated from the intraosseous artery. Thus, the length of the pedicle was extended. Using this technique mostly used for the lunate bone, the length of the pedicle was extended, and therefore, the problem with accessing the scaphoid bone was eliminated.

We applied vascularized grafts from the 4-5 ECA in all of the 15 cases in our series. We obtained grafts with sufficient pedicle length in our cases with avascular necrosis of the proximal pole. We did not encounter any perfusion problem following the preparation and application of the graft. Other than the one case in which union was observed at the 10th week, all cases achieved union in two months.

Successful results have been often reported with the use of VPBGs in nonunion cases [19,20,21]. After a review of the unsuccessful case series in the literature, we saw that factors such as previous surgery, female gender, fixation with K-wires, smoking, humpback deformity and the presence of AVN of the proximal pole affected the success of grafting [22,23,24].

Of these, the fixation method is a major factor that affects the consolidation of the bone graft. Grafting applications without fixation had been performed in nonunions of the scaphoid in the earlier periods, however, today, headless screw designs which are resistant to repetitive loadings, easily applicable cannulated and with a high compression capability are gaining preference.

In their study on scaphoid nonunions, Christodoulou et al. employed three different fixation methods with the non-vascularized bone grafting technique and found no significant difference between the AO mini fragment screw (85%) and the Herbert screw (77%) regarding union rate and time to union, but observed union only in 55% of the cases who were performed fixation with K-wires [25]. Straw et al. applied 1-2 ICSRA grafts and K-wires in their patients and achieved union in 75% of the cases with good blood supply to the proximal pole but in only 11% of the cases with avascular necrosis [26]. In a study where they investigated the cases with AVN of the proximal pole, Chang et al. achieved union in five of the eight cases to whom they applied 1-2 ICSRA (graft) and Herbert screw and in two out of the four cases to whom they applied K-wires. The authors also stated that the use of a single K-wire and extraction in the early period without union led to poor results [27]. As the outcomes of our study have shown, we believe that screw fixation, especially in avascular necrosis cases, provides a more stable fixation and thus increases the success rate in graft consolidation.

There is a negative correlation between smoking and nonunion. Dinah et al. applied cancellous autografts and screws in their patients with nonunion, fixed the variables such as age, fracture location, screw type, time after fracture and duration of postoperative cast application, and achieved union in 40% of the smoking group and in 82.4% of the non-smoking group [28]. In a similar study, Little et al. noted that 36% of the cases in whom they achieved union and 76% of the cases in whom they failed to achieve union were smokers [29]. In a study where they investigated the results of VPBG and screw application, Özalp et al. observed union in 80% of the smoking group and in 95.7% of the non-smoking group [18]. In their series with 30 avascular necrosis cases, Waitayawinyu et al. achieved union in 93% of the cases who were applied 1-2 ICSRA (grafts) and screws, and noted that the two cases with

non-union were both smokers [30]. Choosing VPBGs over conventional grafts in smoking patients may increase the success rate of union. In our study, only two patients were smokers, yet, we did not observe any nonunion following VPBG application.

Various success rates have been reported in the studies performed with VPBGs [31]. This may be explained by the patient-related and surgical differences in publications. All cases in our study group had avascular necrosis of the proximal pole and were male. All cases were performed the same surgical procedure and fixation method. The success of our series may be attributed to no history of previous surgery, the performance of all surgeries by the same senior surgeon and the rigid fixation achieved by the use of screws.

Success is not guaranteed in VPBG applications. The success rate can be increased by the choice of right patient and fracture, attentive surgery and identification of the appropriate bone for graft harvest. Although the 1-2 ICSRA grafts frequently used in scaphoid surgery are close to the pseudoarthrosis site, the diameter of the arteries of the 4-5 ECA grafts supplying blood to the pedicle is wider. This helps vascularity of the pedicle in addition to providing better visualization and decreasing the impact of surgical trauma on the pedicle.

The retrospective design of our study, the absence of a control group and the limited number of cases were the limitations of our study. In addition, we could have used more objective functional scoring systems. Finally, we could utilize CT in evaluating the presence of union, however, we preferred not to use it during our routine assessment in order to avoid the potential harmful effects of radiation. The most significant improvement among our results was with the pain scores. Although we failed to observe a significant improvement in functional scores and wrist ranges of motion, all patients were able to return to work.

The use of VPBGs in scaphoid surgery today is still an application in progress. Future studies with ho-

mogeneous and large comparison groups may more clearly exhibit the role of VPBGs in cases with avascular necrosis of the scaphoid.

Conclusion

The results of our study have shown that vascularized grafts from the 4-5 ECA can be successfully applied in proximal locations in cases with avascular necrosis.

Conflict of interest statement

The authors have no conflicts of interest to declare.

References

1. Mack GR, Bosse MJ, Gelberman RH, Yu E. The natural history of scaphoid nonunion. *J Bone Joint Surg Am* 1984;66:504-9.
2. Schuind F, Haentjens P, Van Innis F. Prognostic factors in the treatment of carpal scaphoid nonunions. *J Hand Surg* 1999;24A:761-76.
3. Alluri RK, Yin C, Iorio ML, Leland H, Wong J, Patel K. Vascularized Bone Grafting in Scaphoid Nonunion : A Review of Patient Centered Outcomes. *Hand (NY)* 2017;12:127-34.
4. Shin AY, Bishop AT. Pedicled vascularized bone grafts for disorders of the carpus: scaphoid nonunion and Kienböck's disease. *J Am Acad Orthop Surg* 2002;10:210-6.
5. Krug EG, Sharma GK, Lozano R. The global burden of injuries. *Am J Public Health* 2000;90:523-6.
6. Ross CE, Mirowsky J. Does employment affect health ? *J Health Soc Behav* 1995;36:230-43.
7. Kuschner SH, Lane CS, Brien WW, Gellman H. Scaphoid fractures and scaphoid nonunion. Diagnosis and treatment. *Orthop Rev* 1994;23:861-71.
8. Steinmann SP, Bishop AT, Berger RA. Use of the 1,2 intercompartmental supraretinacular artery as a vascularized pedicle bone graft for difficult scaphoid nonunion. *J Hand Surg Am* 2002;27:391-401.
9. Sotereanos DG, Darlis NA, Dailiana ZH, Sarris IK, Malizos KN. A capsular based vascularized distal radius graft for proximal pole scaphoid pseudoarthrosis. *J Hand Surg Am* 2006;31:580-7.

10. Zaidenberg C, Siebert JW, Angrigiani C. A new vascularized bone graft for scaphoid nonunion. *J Hand Surg* 1991;16A:474–8.
11. Rizzo M, Moran SL. Vascularized bone grafts and their applications in the treatment of carpal pathology. *Semin Plast Surg* 2008;22:213-27.
12. Cooney WP, Dobyns JH, Linscheid RL. Nonunion of the scaphoid: analysis of the results from bone grafting. *J Hand Surg Am* 1980;5:343–54.
13. Merrell GA, Wolfe SW, Slade JF III. Treatment of scaphoid nonunions: quantitative meta-analysis of the literature. *J Hand Surg Am* 2002;27:685–91.
14. Ribak S, Medina C, Mattar R Jr, Ulson HJ, Etchebhere M. Treatment of scaphoid nonunion with vascularised and nonvascularised dorsal bone grafting from the distal Radius. *Int Orthop* 2010;34:683-8.
15. Bishop AT. Vascularized pedicle grafts from the dorsal distal radius: design and application for carpal pathology. In: Saffar P, Amadio PC, Foucher G, (eds.) *Current Practice in Hand Surgery*. Martin Dunitz Ltd, London, 1997:307–13.
16. Sunagawa T, Bishop AT, Muramatsu K. Role of conventional and vascularized bone grafts in scaphoid nonunion with avascular necrosis: a canine experimental study. *J Hand Surg* 2000;25A:849–59.
17. Sheetz KK, Bishop AT, Berger RA. The arterial blood supply of the distal radius and its potential use in vascularized pedicled bone grafts. *J Hand Surg* 1995;20A:902–14.
18. Özalp T, Öz Ç, Kale G, Erkan S. Scaphoid nonunion treated with vascularised bone graft from dorsal Radius. *Injury* 2015;46 (Suppl 2):S47-52.
19. Steinmann SP, Bishop AT, Berger RA. Use of the 1,2 intercompartmental supraretinacular artery as a vascularized pedicle bone graft for difficult scaphoid nonunion. *J Hand Surg* 2002;27A:391-401.
20. Uerpaiojkit C, Leechavengvongs S, Witoonchart K. Primary vascularized distal radius bone graft for nonunion of the scaphoid. *J Hand Surg* 2000;25B:266–70.
21. Tsai TT, Chao EK, Tu YK, Chen AC, Lee MS, Ueng SW. Management of scaphoid nonunion with avascular necrosis using 1,2-intercompartmental supraretinacular arterial bone grafts. *Chang Gung Med J* 2002;25:321–8.
22. Boyer MI, von Schroeder HP, Axelrod TS. Scaphoid nonunion with avascular necrosis of the proximal pole. Treatment with a vascularized bone graft from the dorsum of the distal radius. *J Hand Surg Br* 1998;23:686–90.
23. Straw RG, Davis TR, Dias JJ. Scaphoid nonunion: treatment with a pedicled vascularized bone graft based on the 1,2 intercompartmental supraretinacular branch of the radial artery. *J Hand Surg Br* 2002;27:413.
24. Chang MA, Bishop AT, Berger RA. The outcomes and complications of 1,2 intercompartmental supraretinacular artery pedicled vascularized bone grafting of scaphoid nonunions. *J Hand Surg Am* 2006;31:387–96.
25. Christodoulou LS, Kitsis CK, Chamberlain ST. Internal fixation of scaphoid nonunion : a comparative study of three methods. *Injury* 2001;32:625-30.
26. Straw RG, Davis TR, Dias JJ. Scaphoid nonunion : treatment with pedicled vascularised bone graft based on the 1,2 intercompartmental supraretinacular branch of the radial artery. *J Hand Surg Br* 2002;27:413.
27. Chang MA, Bishop AT, Moran SL, Shin AY. The outcomes and complications of 1,2-intercompartmental supraretinacular artery pedicled vascularized bone grafting of scaphoid nonunions. *J Hand Surg Am* 2006;31:387-96.
28. Dinah AF, Vickers RH. Smoking increases failure rate of operation for established non-union of the scaphoid bone. *Int Orthop* 2007;31:503-5.
29. Little CP, Burston BJ, Hopkinson-Woolley J, Burge P. Failure of surgery for scaphoid nonunion is associated with smoking. *J Hand Surg Br* 2006;31:252-5.
30. Waitayawinyu T, McCallister WV, Katolik LI,

Schlenker JD, Trumble TE. Outcome after vascularized bone grafting of scaphoid nonunions with avascular necrosis. *J Hand Surg Am* 2009;34:387-94.

31. Boyer MI, Von Schroeder HP, Axelrod TS.

Scaphoid nonunion with avascular necrosis of the proximal pole: treatment with a vascularized bone graft from the dorsum of the distal radius. *J Hand Surg* 1998;23B:686-90.

© 2019 Turkish Society for Surgery of the Hand and Upper Exremity. This is an open access article licensed under the terms of the Creative Commons Attribution NonCommercial ShareAlike 4.0 (<https://creativecommons.org/licenses/by-nc-sa/4.0/>) which permits unrestricted, noncommercial use, distribution and reproduction in any medium, provided the work is properly cited.