



Can fracture healing be accelerated by serum transfer in head trauma cases? An experimental head trauma model in rats

Abdülkadir Sarı, MD¹, Yaşar Mahsut Dinçel, MD¹, Mehmet Ümit Çetin, MD¹, Sevda İnan, MD²

¹Department of Orthopedics and Traumatology, Namık Kemal University Faculty of Medicine, Tekirdağ, Turkey

²Department of Pathology, Namık Kemal University Faculty of Veterinary Medicine, Tekirdağ, Turkey

Fracture healing is a very complex process.^[1] Problems in fracture repair are frequently encountered and cause therapeutic problems that increase the treatment costs.^[2] High rates of union and abundant callus formation following long bone fractures accompanied by head trauma have been known for many years.^[3] Until today, the transfer of this positive effect has only been shown in *in vitro* studies;^[4] in the literature, unfortunately, there are no *in vivo* studies available confirming this effect.

In the present study, we aimed to investigate whether the positive union effect caused by head trauma could be transmitted between individuals in the light of radiological and histopathological data and existing literature.

MATERIALS AND METHODS

This experimental study was conducted at Namık Kemal University, Experimental Animal Application

Received: February 02, 2021

Accepted: March 28, 2021

Published online: June 11, 2021

Correspondence: Abdülkadir Sarı, MD. Namık Kemal Üniversitesi Tıp Fakültesi Ortopedi ve Travmatoloji Anabilim Dalı, 59030 Tekirdağ, Türkiye.

E-mail: asari@nku.edu.tr

Doi: 10.52312/jdrs.2021.8

Citation: Sarı A, Dinçel YM, Çetin MÜ, İnan S. Can fracture healing be accelerated by serum transfer in head trauma cases? An experimental head trauma model in rats. Jt Dis Relat Surg 2021;32(2):306-312.

©2021 All right reserved by the Turkish Joint Diseases Foundation

This is an open access article under the terms of the Creative Commons Attribution-NonCommercial License, which permits use, distribution and reproduction in any medium, provided the original work is properly cited and is not used for commercial purposes (<http://creativecommons.org/licenses/by-nc/4.0/>).

ABSTRACT

Objectives: In this study, we aimed to investigate whether the positive union effect caused by head trauma could be transferred between individuals.

Materials and methods: Seventy-two male rats with an average weight of 375 g were used in this study and divided into four groups including 18 in each group. Group 1 consisted of serum donor rats that were exposed to head trauma, while Group 2 consisted of study rats with long bone fractures that were given the serum obtained from the rats in Group 1, Group 3 included control rats with isolated long bone fractures, and Group 4 included control rats with both head trauma and long bone fractures. For radiological evaluation, the ratio of the width of the callus to the width of the neighboring diaphysis was considered as the callus-to-diaphyseal ratio in the study and control groups. Histopathological and radiological evaluations was made on Days 10, 20, and 30.

Results: In evaluation of the radiological data regarding the callus-to-diaphyseal ratio, Group 3 was found to have significantly lower radiological values than Group 4 on Day 10 ($p=0.006$). Group 2 had significantly higher values than Group 3 ($p=0.02$). On Day 20, Group 2 exhibited significantly higher radiological values than Group 3 ($p=0.004$), but lower than Group 4 ($p=0.032$). As for Day 30, Group 2 exhibited significantly higher radiological values than Group 3, but lower than Group 4 ($p=0.001$). In the evaluation of the Huo scores obtained for histopathological evaluation, there was no significant difference among the groups on Days 10, 20, and 30 ($p=0.295$, $p=0.569$, and $p=0.729$, respectively).

Conclusion: Our study results suggest that the osteoinductive effect after head trauma can be transmitted between individuals by means of serum transfer.

Keywords: Fracture healing; histopathology; rat; serum transfer; traumatic brain injury.

and Research Laboratory between February 2020 and June 2020. The study protocol was approved by the Namık Kemal University Faculty of Medicine Ethics Committee for Animal Testing (Date: 2019-02-20, No: T2019-232). All animals were treated in accordance with the Guide for the Care and Use of Laboratory Animals. Seventy-two male Wistar albino rats with an average age of 3.5 months and an average weight

TABLE I				
Grouping of the animals included in the study				
	Group 1	Group 2	Group 3	Group 4
	n	n	n	n
Number of rats	18	18	18	18
Sacrificiation days	1-7	10-20-30	10-20-30	10-20-30
Number of femur specimens	-	6-6-6	6-6-6	6-6-6

Group 1 (donor group); Group 2 (study group with femur fractures that were given serum); Group 3 (control group with femur fractures); Group 4 (control group with femur fractures + head trauma).

of 375 g were used for the study. The rats included in the study were preoperatively monitored for 48 h in the laboratory and kept at 22°C and under 12-h light-dark cycles. A standard pellet diet and water ad libitum were provided.

The rats were randomly divided into four groups of 18 rats each. Group 1 (donor group) consisted of serum donor rats that were exposed to head trauma, while Group 2 consisted of study rats with long bone fractures that were given the serum obtained from the rats in Group 1, Group 3 included control rats with isolated long bone fractures, and Group 4 included control rats with both head trauma and long bone fractures (Table I). Group 1 was further divided into two sub-subgroups (a and b), and the other three groups into three sub-subgroups (a, b, c) according to

sacrificiation times. The trauma models in Groups 1 and 2 were created on the same day, while head trauma and long bone fractures were also created on the same day in Group 4.

Our goal with the experimental model was to create an animal model similar to that of humans with closed head trauma. Therefore, the brain injury model which could be created by craniotomy was avoided. The experimental closed head trauma model was created with an apparatus prepared according to the Marmarou technique (Figure 1a).^[5] In order for the rats to survive after brain trauma and maintain their nutritional functions, we planned not to apply a force to the head over 0.5 joule.^[6] Thus, the upper limit was set at 50 g for the weight to be dropped and one meter for height.

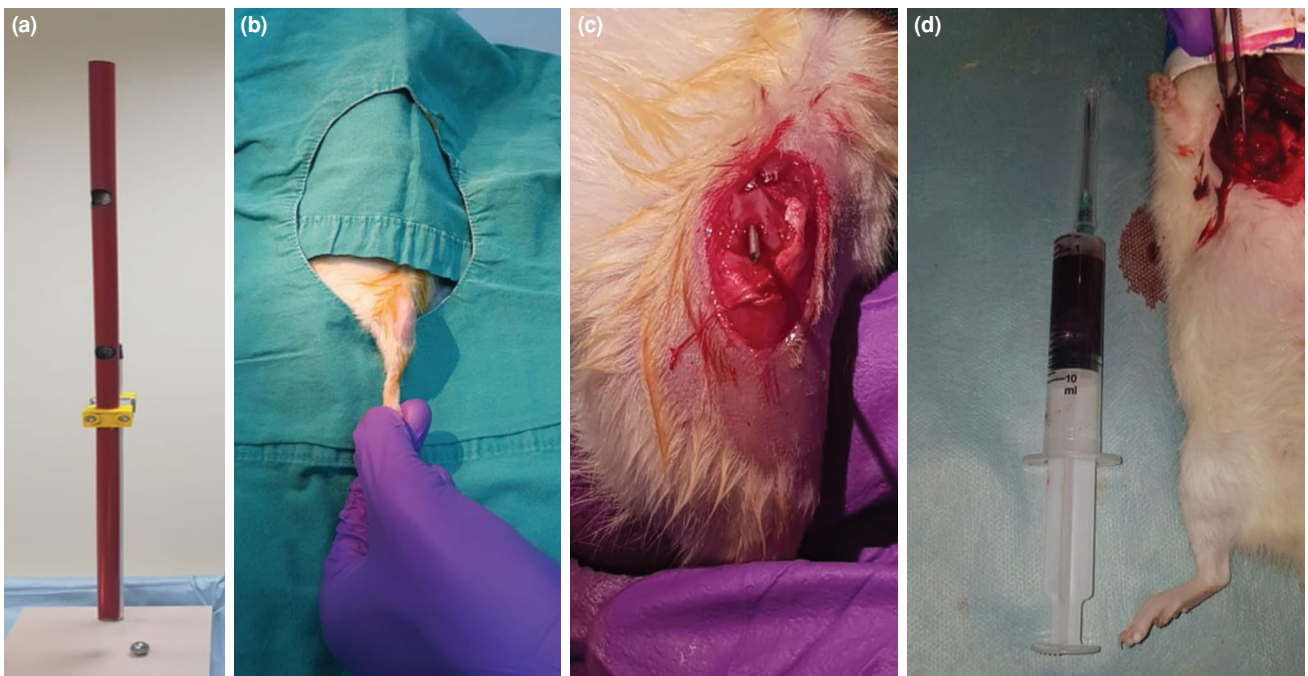


FIGURE 1. (a) Device used for the creation of the closed head trauma model. (b) Rats were shaved and disinfected with povidone-iodine. (c) Intramedullary insertion of the Kirschner wire in the femur. (d) Drawing blood from the heart after thoracotomy.

All procedures were performed under general anesthesia. Isoflurane (FORANE; Abbott Laboratories, Abbott Park, IL, USA) was used for inhalation with a dose of 4% for induction and a dose of 2% for maintenance. Postoperative pain management was performed by subcutaneous administration of 3 to 5 mg/kg of carprofen (RIMADYL; Pfizer Inc., New York, NY, USA) with 12-h intervals within the first 24 h. One-time subcutaneous dose of gentamicin 8 mg/kg (GENTHAVER; Osel Ilac Sanayi ve Tic. A.S., Istanbul, Turkey) was given for prophylaxis before surgery to the rats that underwent fracture fixation.

Before the femoral fracture was created, the left knee was entered using an anterior approach under sterile conditions, the patella was lateralized, and the femoral condyles were exposed. First, the femoral canal was prepared using a 1.2-mm Kirschner wire, followed by the insertion of a 1-mm Kirschner wire into the femur. The proximal of the wire was slightly bent to prevent the wire from retracting back into the joint.^[7] After cutting the wire at the joint level, the wound was closed with 3/0 absorbable sutures and 3/0 silk sutures (Figure 1b and c). For the fracture model, the experimental one-sided closed fracture model was created on the left legs of the rats according to the principles defined by Bonnarens and Einhorn^[8] and used in several experimental fracture healing studies.^[9,10] A 150 g weight was dropped from one meter height to the thigh.

Four rats that were observed to have developed segmental fractures during the radiological controls were excluded from the study and were substituted with new rats. After the procedure, the rats were

placed in cages in groups of four and were allowed to move freely.

The rats in Group 1a were sacrificed 24 h after the procedure, while rats in Group 1b were sacrificed on Day 7 by taking blood from their hearts after open thoracotomy (Figure 1d). To prevent the change in serum content due to hemolysis in the blood samples obtained, the blood was discharged with a 45° inclination after the needle of the injector was removed. The samples were centrifuged at 3,000 rpm for 10 min and the serum part was separated. Serums (2 mL) obtained from Group 1a were given to Groups 2a, 2b and 2c without delay, and the serums (2 mL) obtained from Group 1b were given intraperitoneally to Groups 2a, 2b and 2c. The effect was standardized by giving equal amounts of serum (2 mL) to each rat in Group 2 each time. Following the serum administration, Group 2 rats did not demonstrate any allergic or reject reactions. The rats in Groups 2a, 3a and 4a were sacrificed on Day 10, the rats in Groups 2b, 3b and 4b on Day 20, and the rats in Groups 2c, 3c and 4c on Day 30 via cervical dislocation performed under high-dose anesthesia.

After sacrifice, femoral bones were disarticulated from the hip joint and direct radiographs were taken (Figure 2a-c). In all groups, the radiographs taken on Days 10, 20, and 30 were evaluated according to the callus-to-diaphyseal ratio defined by Spencer.^[11] In this measurement, we took the ratio of the width of the callus at its widest point to the width of the diaphysis adjacent to the healing fracture site; with both measurements being taken

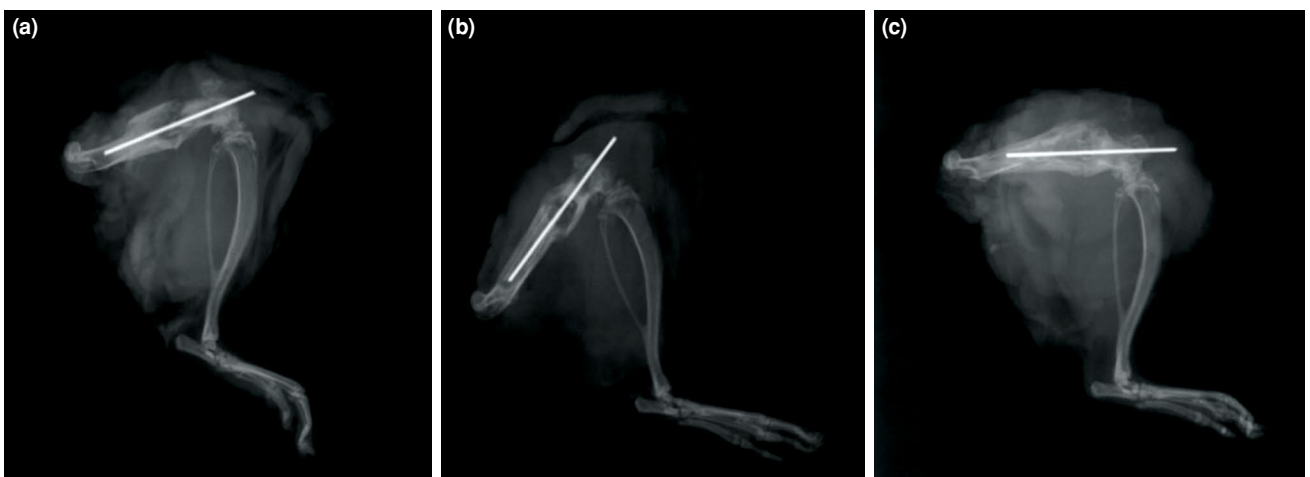


FIGURE 2. (a) Postoperative 30th day X-ray image from the study group given serum (Group 2c). (b) Postoperative 30th day X-ray image from the control group with isolated femur fractures (Group 3c). (c) Postoperative 30th day X-ray image from the control group with concomitant head trauma and femur fractures (Group 4c).

by drawing right angles to the long axis of the bone. The measurements were carried out by an orthopedic surgeon who was blinded to the group allocation.

Histopathological examinations were performed by a veterinary pathologist who was blinded to the study design and setting. After the rats were euthanized, the bone tissue from each group were fixed in 10% phosphate buffered formalin solution at room temperature and then decalcified in 10% formic acid solution. The specimens were neutralized with ammonia solution for 30 min, washed for one day, dehydrated in graded ethanol and embedded in paraffin. Five-micrometer thick sections were mounted and stained with hematoxylin and eosin (H-E). Each slide was evaluated semi-quantitatively under the light microscope (Olympus CX41; Olympus Corporation, Tokyo, Japan) by selecting four different sections and classified according to the histological grading system of Huo et al.^[12] (Figure 3, Table II).

Statistical analysis

Statistical analysis was performed using the NCSS version 2007 software (NCSS LLC, Kaysville, UT, USA). Descriptive data were expressed in mean \pm standard deviation (SD), median (min-max), or number and frequency. The distribution of the data was evaluated using the Shapiro-Wilk test. The Kruskal-Wallis test was used to compare the quantitative data from three or more groups that did not meet a normal distribution. The Friedman test was utilized for comparisons of three time periods and above, and the Wilcoxon test was used to determine the differences. A p value of <0.05 was considered statistically significant.

RESULTS

Callus-to-diaphyseal ratios according to Spencer^[11] were obtained from the lateral radiographs taken after sacrifice on Days 10, 20, and 30. In all three groups, radiological scores showed a gradual

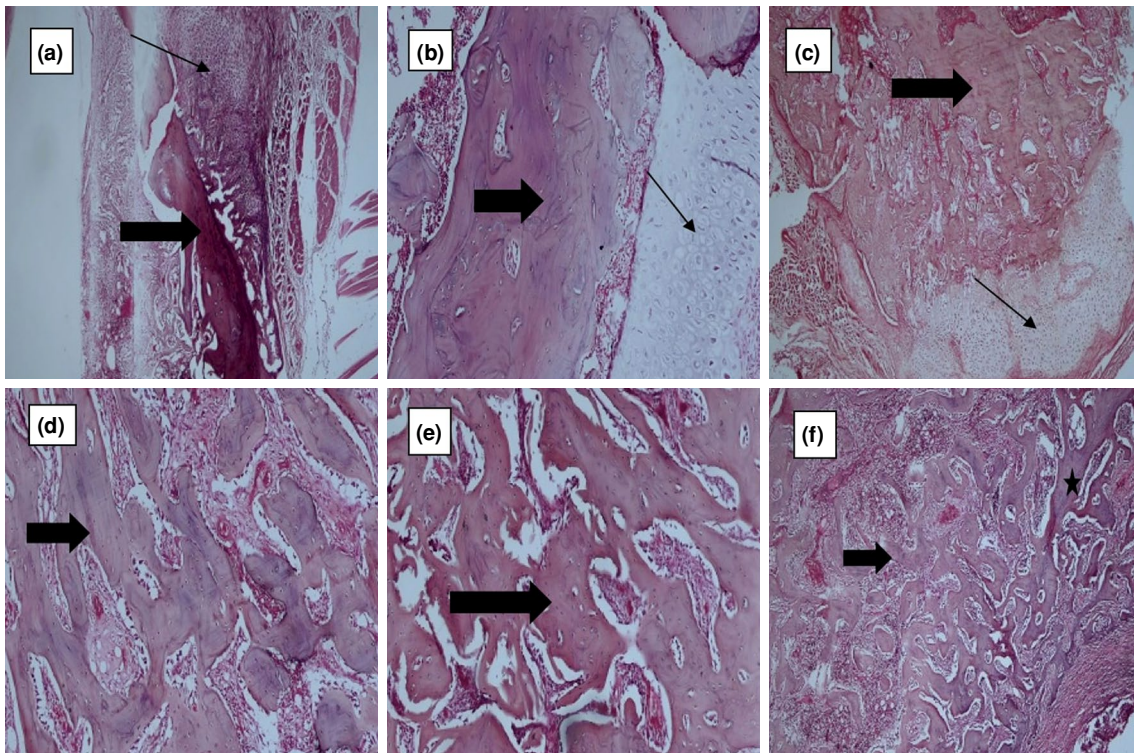


FIGURE 3. Histopathological appearance of the fracture. The thin arrows indicate cartilage tissues, the thick arrows show immature (woven) bone tissues, and the star shape point to mature bone tissues. (a) Marked mainly cartilage tissue and small amount of immature tissue (Group 3a) (H-E, $\times 40$ magnification). (b) Marked equal amount of cartilage tissue and immature bone tissue (Group 3b) (H-E, $\times 100$ magnification). (c) Marked mainly immature bone tissue and small amount cartilage tissue (Group 4b) (H-E, $\times 40$ magnification). (d) Marked immature bone tissue (respectively, Group 2c) (H-E, $\times 100$ magnification). (e) Marked immature bone tissue (respectively, Group 3c) (H-E, $\times 100$ magnification). (f) Marked immature bone tissue and small amount of mature bone tissue (Group 4c) (H-E, $\times 40$ magnification).

TABLE II	
Histological scoring system of Huo et al. ^[12]	
Score	Histological findings
1	Fibrous tissue
2	A large amount of fibrous tissue and a small amount of cartilage tissue
3	Equal ratio of fibrous tissue and cartilage tissue
4	A large amount of cartilage tissue and a small amount of fibrous tissue
5	Cartilaginous tissue
6	A large amount of cartilage tissue and a small amount of immature bone tissue
7	Equal ratio of cartilage tissue and immature bone tissue
8	A large amount of immature bone tissue and a small amount of cartilage tissue
9	Fracture healing with immature bone
10	Fracture healing with mature bone

increase from Day 10 to 30 ($p=0.002$ for Groups 2, 3 and 4 each).

Statistically significant radiological differences were detected among the groups at each time period ($p<0.05$). On Day 10, Group 3a showed statistically significant lower radiological values than Group 4a ($p=0.006$), and Group 2a had statistically significant higher values than Group 3a ($p=0.02$). On Day 20, Group 2b exhibited significantly higher radiological values than Group 3b ($p=0.004$), but lower than Group 4b ($p=0.032$). Group 4b also had significantly higher values than Group 3b ($p=0.004$). As for Day 30, group 2c exhibited higher radiological values than Group 3c, but lower than Group 4c ($p=0.001$) (Table III).

The radiological score in Group 2a on Day 10 was significantly lower than the Group 2b values

on Day 20 ($p=0.001$). Similarly, the radiological score in Group 2a on Day 10 and the score in Group 2b on Day 20 was significantly lower than the score in Group 2c on Day 30 ($p=0.001$). The radiological score in Group 3c on Day 30 was significantly higher than the values in Groups 3a and 3b ($p=0.001$). The radiological score in Group 3b was higher than that of Group 3a ($p=0.001$). Also, the radiological score in Group 4c on Day 30 was significantly higher than the values in Groups 4a and 4b ($p=0.001$). The radiological score in Group 4b was higher than the score in Group 4a ($p=0.001$).

In evaluation of the Huo scores obtained for histopathological evaluation, there was no statistically significant difference among the groups on Days 10, 20, and 30 ($p=0.295$, $p=0.569$, and $p=0.729$, respectively) (Table IV).

TABLE III					
Comparison of the radiological measurements in the groups					
	n	Mean±SD	Median	Min-Max	p
Day 10					
Group 2a	6	1.4±0.2	1.45	1.2-1.6	0.012*
Group 3a	6	1.2±0.1	1.2	1.1-1.3	
Group 4a	6	1.5±0.1	1.5	1.3-1.6	
Day 20					
Group 2b	6	2.2±0.2	2.25	2-2.4	0.001†
Group 3b	6	1.9±0.1	1.9	1.8-2	
Group 4b	6	2.4±0.1	2.4	2.3-2.5	
Day 30					
Group 2c	6	2.7±0.1	2.7	2.6-2.8	0.005†
Group 3c	6	2.5±0.1	2.5	2.4-2.6	
Group 4c	6	2.8±0.2	2.75	2.6-3	

SD: Standard deviation; Kruskal-Wallis test; * $p<0.05$; † $p<0.01$.

TABLE IV Comparison of the histopathological scores by groups					
	n	Mean±SD	Median	Min-Max	p*
Day 10					
Group 2a	6	6.3±0.5	6	6-7	0.295
Group 3a	6	6±0.6	6	5-7	
Group 4a	6	6.7±0.8	6.5	6-8	
Day 20					
Group 2b	6	7.5±0.6	7.5	7-8	0.569
Group 3b	6	7.3±0.8	7.5	6-8	
Group 4b	6	7.8±0.8	8	7-9	
Day 30					
Group 2c	6	9±0.6	9	8-10	0.729
Group 3c	6	9±0	9	9-9	
Group 4c	6	9.2±0.4	9	9-10	

SD: Standard deviation; * Kruskal-Wallis test.

DISCUSSION

Our study shows that taking serum samples from patients with head trauma and transferring them to patients with long bone fractures accelerates the union process and supports the formation of radiologically significant callus in the early period.

There is a consensus in the literature that fracture healing in the long bones is positively affected after traumatic brain injury.^[13] Giannoudis et al.^[14] reported that femoral fractures after head trauma could heal faster with a greater callus-to-diaphyseal ratio. Arik et al.^[15] found a significantly larger callus mass, compared to the control group, in the experimental rat models on the first and third weeks after head trauma. The authors concluded that head trauma increased the fracture healing speed in the early period.

The mechanisms affecting fracture union after head trauma are still not fully understood. In a recent study,^[16] it was claimed that the combination of relative inhibition of the sympathetic nervous system and non-hormonal mechanisms was effective. In the same study, parathyroid hormone levels peaked in the first 24 h in human serum samples from cases with head trauma and from cases who had head trauma accompanied by long bone fractures, and that both groups had higher values than the control group with isolated long bone fractures. In another study, parathyroid hormone levels in the samples taken from human cases peaked in the first 6 to 24 h after head trauma, and the osteoinductive effect reached its maximum level in 24 h after traumatic brain injury and decreased slowly after the first week.^[4] In our study,

serum samples were obtained from the donor group at 24 h and at the first week, and were transferred to cases with femur fractures in accordance with the literature data.

Although the phases of fracture healing differ very little in experimental rat studies, it may be classified as follows: hematoma (Days 1 to 5), callus formation (Days 5 to 10), mineralization (Days 10 to 20), and hardening of the callus (Days 20 to 28), followed by the bone remodeling phase.^[17] In another study, hematoma and inflammation phase were observed on Day 7, the callus phase on Day 14, and the ossification phase on Day 21.^[18] The 10th day in our study delineates the early callus phase of fracture healing, the 20th day delineates the mineralization phase, and the 30th day the ossification phase before bone remodeling.

In the current literature, there are studies investigating the effects of osteoinductive serums on cell cultures in an *in vitro* setting. Bidner et al.^[19] showed that serums obtained from head trauma cases caused an increased proliferation effect on rat osteoblast cell cultures, compared to serums obtained from healthy controls and cases with isolated fractures. Gautschi et al.^[4] showed that serum samples obtained from cases with long bone fractures accompanied by head trauma had a greater proliferative effect on human fetal osteoblastic cells and human osteoblasts, compared to serums obtained from cases with isolated head traumas and cases with isolated long bone fractures. Boes et al.^[20] also demonstrated that, when incubated with serum from brain-damaged rats, human stromal stem cells

had reproduced in higher numbers than what was anticipated and suggested that brain-derived factors mediated a mitogenic effect on osteoprogenitor cells through the bloodstream.

In our study, the *in vivo* efficacy of the osteoinductive effect due to head trauma was investigated for the first time. When callus-to-diaphyseal ratios were examined, we found that callus formation increased from Day 10 to Day 30 in all groups. We also observed that the serum-transferred group had better radiological scores than the isolated fracture group in all periods after fracture. Although there was no statistically significant difference among the histopathological scores of the groups, microscopic examinations confirmed a predominant presence of cartilage or equal presence of cartilage and immature bone tissue in all groups on Days 10 and 20. On Day 30, a denser immature bone tissue and less cartilage tissue were observed. In all measurements, Group 4 had more dense immature tissue and less collagen tissue than Groups 2 and 3 and demonstrated a better healing process. Radiologically, our results demonstrate that serum transfer had a positive effect on the early callus formation and mineralization periods of fracture healing, although they are not histopathologically confirmed. We also noticed that this effect continued in the early remodeling phase.

Our study has some limitations. First, the rats with head trauma and long bone fractures could be added to the study as a serum donor group instead of those only with head trauma. Second, the union of long bone fractures could be evaluated biomechanically. In our study, possible infection and nonunion conditions were reduced by avoiding the creation of an open fracture model, and cases with partial fractures that occurred after the closed fracture model were excluded. Finally, micro-computed tomography could have been used for radiological evaluation, as it would be more objective, and Spencer scoring was used instead of Lane and Sandhu scoring.

In conclusion, our study showed that the osteoinductive effect after head trauma can be transmitted between individuals by means of serum transfer. We believe that the present study results would provide an additional contribution to the development of new therapeutic modalities following future studies on humans.

Declaration of conflicting interests

The authors declared no conflicts of interest with respect to the authorship and/or publication of this article.

Funding

The authors received no financial support for the research and/or authorship of this article.

REFERENCES

- Sathyendra V, Darowish M. Basic science of bone healing. *Hand Clin* 2013;29:473-81.
- Szczęśny G. Fracture healing and its disturbances. A literature review. *Ortop Traumatol Rehabil* 2015;17:437-54.
- Newman RJ, Stone MH, Mukherjee SK. Accelerated fracture union in association with severe head injury. *Injury* 1987;18:241-6.
- Gautschi OP, Cadosch D, Frey SP, Skirving AP, Filgueira L, Zellweger R. Serum-mediated osteogenic effect in traumatic brain-injured patients. *ANZ J Surg* 2009;79:449-55.
- Marmarou A, Foda MA, van den Brink W, Campbell J, Kita H, Demetriadou K. A new model of diffuse brain injury in rats. Part I: Pathophysiology and biomechanics. *J Neurosurg* 1994;80:291-300.
- Silva Ddos S, Brito JN, Ibiapina JO, Lima MF, Medeiros AR, Queiroz BH, et al. Traumatic brain injury: Clinical and pathological parameters in an experimental weightdrop model. *Acta Cir Bras* 2011;26:94-100.
- Dincel YM, Alagoz E, Arıkan Y, Çağlar AK, Doğru SC, Ortes F, et al. Biomechanical, histological, and radiological effects of different phosphodiesterase inhibitors on femoral fracture healing in rats. *J Orthop Surg (Hong Kong)* 2018;26:230949901877885.
- Bonnarens F, Einhorn TA. Production of a standard closed fracture in laboratory animal bone. *J Orthop Res* 1984;2:97-101.
- Koçkara N, Sofu H, İssin A, Çetinkaya M, Tayfur M, Süleyman B. Pregabalin does not affect fracture healing adversely. *Eklemler Hastalıkları Cerrahisi* 2017;28:19-24.
- Halıcı M, Öner M, Güney A, Canöz Ö, Narin F, Halıcı C. Melatonin promotes fracture healing in the rat model. *Eklemler Hastalıkları Cerrahisi* 2010;21:172-7.
- Spencer RF. The effect of head injury on fracture healing. A quantitative assessment. *J Bone Joint Surg [Br]* 1987;69:525-8.
- Huo MH, Troiano NW, Pelker RR, Gundersen CM, Friedlaender GE. The influence of ibuprofen on fracture repair: Biomechanical, biochemical, histologic, and histomorphometric parameters in rats. *J Orthop Res* 1991;9:383-90.
- Rockwood CA, Green DP. Bone and joint healing. In: Koval KJ, Bucholz RW, Heckman JD, Court-Brown C, Tornetta P, editors. *Rockwood and Green's Fractures in Adults*. Chapter 8. 6th ed. Philadelphia: Lippincott; 2006. p. 297-312.
- Giannoudis PV, Mushtaq S, Harwood P, Kambhampati S, Dimoutsos M, Stavrou Z, et al. Accelerated bone healing and excessive callus formation in patients with femoral fracture and head injury. *Injury* 2006;37 Suppl 3:S18-24.
- Arık M, Ekinci Y, Gürbüz K, Batın S. The effects of focal brain damage on fracture healing: An experimental rat study. *Eklemler Hastalıkları Cerrahisi* 2019;30:267-74.
- Khallaf FG, Kehinde EO, Hussein S. Bone healing and hormonal bioassay in patients with long-bone fractures and concomitant head injury. *Med Princ Pract* 2016;25:336-42.
- Schmidmaier G, Wildemann B, Heeger J, Gäbelein T, Flyvbjerg A, Bail HJ, et al. Improvement of fracture healing by systemic administration of growth hormone and local application of insulin-like growth factor-1 and transforming growth factor-beta1. *Bone* 2002;31:165-72.
- Alıç T, Çıraklı A, Şahin Y, Tomak Y. Effects of cilostazol on fracture healing: An experimental study. *Acta Orthop Traumatol Turc* 2016;50:103-10.
- Bidner SM, Rubins IM, Desjardins JV, Zukor DJ, Goltzman D. Evidence for a humoral mechanism for enhanced osteogenesis after head injury. *J Bone Joint Surg [Am]* 1990;72:1144-9.
- Boes M, Kain M, Kakar S, Nicholls F, Cullinane D, Gerstenfeld L, et al. Osteogenic effects of traumatic brain injury on experimental fracture-healing. *J Bone Joint Surg [Am]* 2006;88:738-43.