

Digital Skin Ulceration and Acro-Osteolysis: A Rare Presentation of Severe Carpal Tunnel Syndrome

Dear Editor,

Carpal tunnel syndrome (CTS), an entrapment neuropathy, rarely presents with digital skin ulcers and acro-osteolysis (AO).^[1]

A 69-year-old female nonsmoker presented with a painless skin ulcer on the second left finger for 2 weeks and swelling of the same digit for 6 years duration. She had no symptoms of Raynaud phenomenon and no history of systemic illness, exposure to chemicals, or trauma. There was no family history of AO. Dermatological examination revealed superficial ulceration on the tip of the second distal phalanx of the left hand, Heberden's nodes, and shortening and swelling of the same digit [Figure 1]. Radial, brachial, and ulnar pulses were normal with cold peripheries. Joint contracture or systemic sclerosis-like skin changes were not detected. The patient did not have any thickened peripheral nerve trunk or tenderness. She had no classic skin lesions of leprosy. The patient's thermal and touch sensations were normal, yet she had a loss of

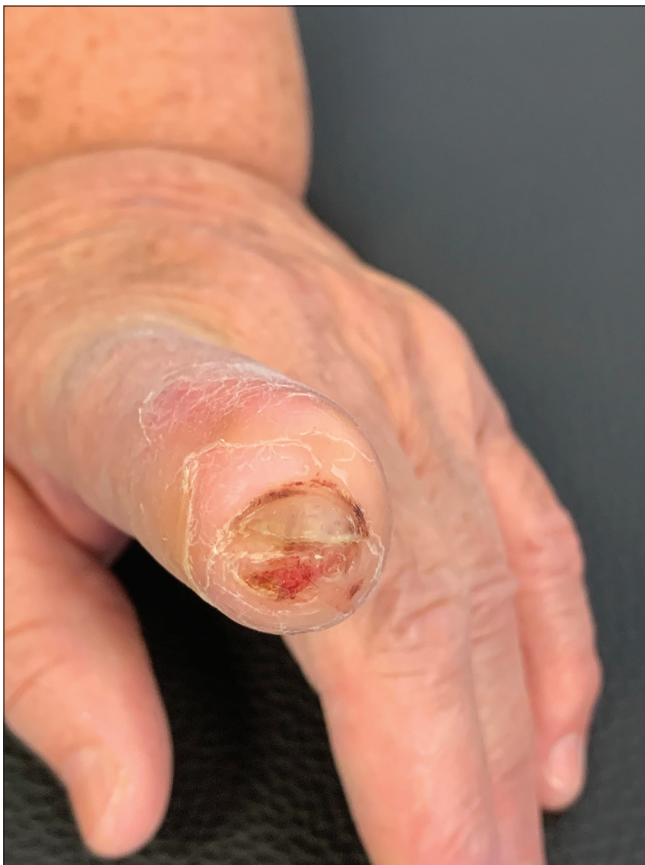

Figure 1: Skin ulceration, shortening, and swelling on the second distal phalanx of the left hand

sensation to pain on the affected finger and surrounding skin. Tinel and Phalen signs were positive. The radiography of the left hand revealed AO of the second left terminal phalanx along with signs of osteoarthritis without calcinosis [Figure 2]. Bone scintigraphy demonstrated degenerative changes without any malignant/metastatic diseases. Histopathological examination revealed findings of wound healing process without evidence of malignancy, sarcoidosis, or leprosy.

A blood evaluation revealed a low-titer (<1/320) antinuclear antibody positivity with a nucleolar pattern, negative anti-Sjögren's-syndrome-related antigen A (SSA), anti-Sjögren's-syndrome-related antigen B (SSB), anti-Jo1, anti-Scleroderma-70, anti-ribonucleoprotein (RNP), anti-Smith, anti-histone antibodies, rheumatoid factor, and anti-cyclic citrullinated peptide (CCP). Complete blood count, renal and liver function tests, serum glucose and electrolytes, creatine kinase, thyroid-stimulating hormone, erythrocyte sedimentation rate, C-reactive protein, and complete urinalysis were all within normal range. Skin smears were negative for acid-fast bacilli.

Doppler ultrasound scan indicated normal blood flow patterns in axillary, brachial, radial, and ulnar arteries. Electroneuromyography (ENMG) showed a bilateral moderate to severe CTS with bilateral loss of sensory and motor function in the median nerve.

Given the results of work-up, skin ulcers and AO were attributed to underlying CTS after excluding the other well-known causes of AO which are exposure to polyvinyl chloride, repetitive trauma, rheumatic diseases, Raynaud syndrome, leprosy, diabetes mellitus, hyperparathyroidism, sarcoidosis, and genetic disorders.^[2] Pure neuritic leprosy (PNL) may also show the same ENMG findings seen in CTS, and positive

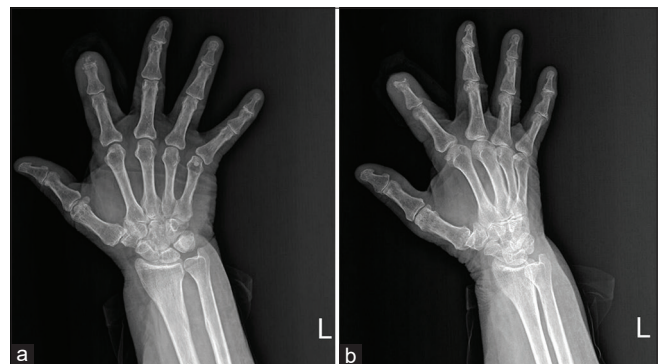


Figure 2: Radiography of the left hand revealed acro-osteolysis of the second left terminal phalanx. (a) Anteroposterior view. (b) Oblique view

Tinel and Phalen signs; however, due to the absence of thickened peripheral nerve trunks and tenderness, negative skin smears, and histopathological findings, PNL diagnosis was ruled out. In addition, Turkey is not an endemic region for leprosy, the patient did not have any history of travel to an endemic region or previous residence, or any family history and apparent exposure history to leprosy or hunting.^[3]

The skin ulcer improved with topical therapy, yet new digital ulcers were observed on the second and third digits during follow-up visits. The patient was referred to the hand surgery department for surgical decompression.

Skin ulcers and AO due to CTS probably result from compression of the sensory and autonomic fibers of the median nerve in more severe cases.^[1] Raynaud phenomenon, color changes of the skin, edema, and swelling of the fingers with subsequent sclerotic skin changes may also be seen due to the impaired vasomotor function.^[4] Furthermore, the sensorial deficit can facilitate repetitive physical and thermal microtraumas. The definitive treatment of severe CTS is surgical decompression after which skin ulcers may improve, yet AO is irreversible.^[1]

The role of osteoclasts in osteoarthritic bone and cartilage degradation has been shown previously.^[5] It has been reported that increased osteoclast formation and higher vascular endothelial growth factor (VEGF) levels may contribute to AO in systemic sclerosis patients representing an association between osteoarthritis and AO.^[6] Thus, the coexistence of progressive osteoarthritis may contribute to the occurrence of AO in our patient.

Skin ulceration with AO due to CTS has rarely been reported. Early diagnosis of CTS is vital to prevent irreversible bone damage.

Declaration of patient consent

The authors certify that they have obtained all appropriate patient consent forms. In the form, the patient(s) has/have given his/her/their consent for his/her/their images and other clinical information to be reported in the journal. The patients understand that their names and initials will not be published and due efforts will be made to conceal their identity, but anonymity cannot be guaranteed.

Financial support and sponsorship

Nil.

Conflicts of interest

There are no conflicts of interest.

Ozge Zorlu, Sevil Karabağ¹

Departments of Dermatology and Venereology and ¹Pathology, Tekirdag Namik Kemal University School of Medicine, Tekirdag, Turkey


Address for correspondence:

Dr. Ozge Zorlu,
Department of Dermatology and Venereology, Tekirdag Namik Kemal University School of Medicine, Tekirdag - 59100, Turkey.
E-mail: zorluzg@gmail.com

References

- Natale M, Spennato P, Bocchetti A, Fratta M, Savarese L, Rotondo M. Ulcerative and mutilating variant of carpal tunnel syndrome. *Acta Neurochir* 2005;147:905-8.
- Botou A, Bangeas A, Alexiou I, Sakkas LI. Acro-osteolysis. *Clin Rheumatol* 2017;36:9-14.
- Rao PN, Suneetha S. Pure neuritic leprosy: Current status and relevance. *Indian J Dermatol Venereol Leprol* 2016; 82:252-61.
- Vergheze J, Galanopoulou AS, Herskovitz S. Autonomic dysfunction in idiopathic carpal tunnel syndrome. *Muscle Nerve* 2000;23:1209-13.
- Löfvall H, Newbould H, Karsdal MA, Dziejgiel MH, Richter J, Henriksen K, *et al.* Osteoclasts degrade bone and cartilage knee joint compartments through different resorption processes. *Arthritis Res Ther* 2018;20:67.
- Park JK, Fava A, Carrino J, Del Grande F, Rosen A, Boin F. Association of acroosteolysis with enhanced osteoclastogenesis and higher blood levels of vascular endothelial growth factor in systemic sclerosis. *Arthritis Rheumatol* 2016;68:201-9.

This is an open access journal, and articles are distributed under the terms of the Creative Commons Attribution-NonCommercial-ShareAlike 4.0 license, which allows others to remix, tweak, and build upon the work non-commercially, as long as appropriate credit is given and the new creations are licensed under the identical terms.

Access this article online	
Website: www.idoj.in	Quick Response Code 
DOI: 10.4103/idoj.idoj_92_22	

How to cite this article: Zorlu O, Karabağ S. Digital skin ulceration and acro-osteolysis: A rare presentation of severe carpal tunnel syndrome. *Indian Dermatol Online J* 2022;13:798-9.

Received: 12-Feb-2022. **Revised:** 18-Apr-2022.

Accepted: 22-Apr-2022. **Published:** 18-Jul-2022.

© 2022 Indian Dermatology Online Journal | Published by Wolters Kluwer - Medknow

Copyright of Indian Dermatology Online Journal is the property of Wolters Kluwer India Pvt Ltd and its content may not be copied or emailed to multiple sites or posted to a listserv without the copyright holder's express written permission. However, users may print, download, or email articles for individual use.